Ultrasound of malignant testicular lesions

Arne Hørlyck
Department of Radiology
Aarhus University Hospital, Skejby



Testis

Ultrasound is fantastic !!



DURS
Danish Society of Ultrasonology

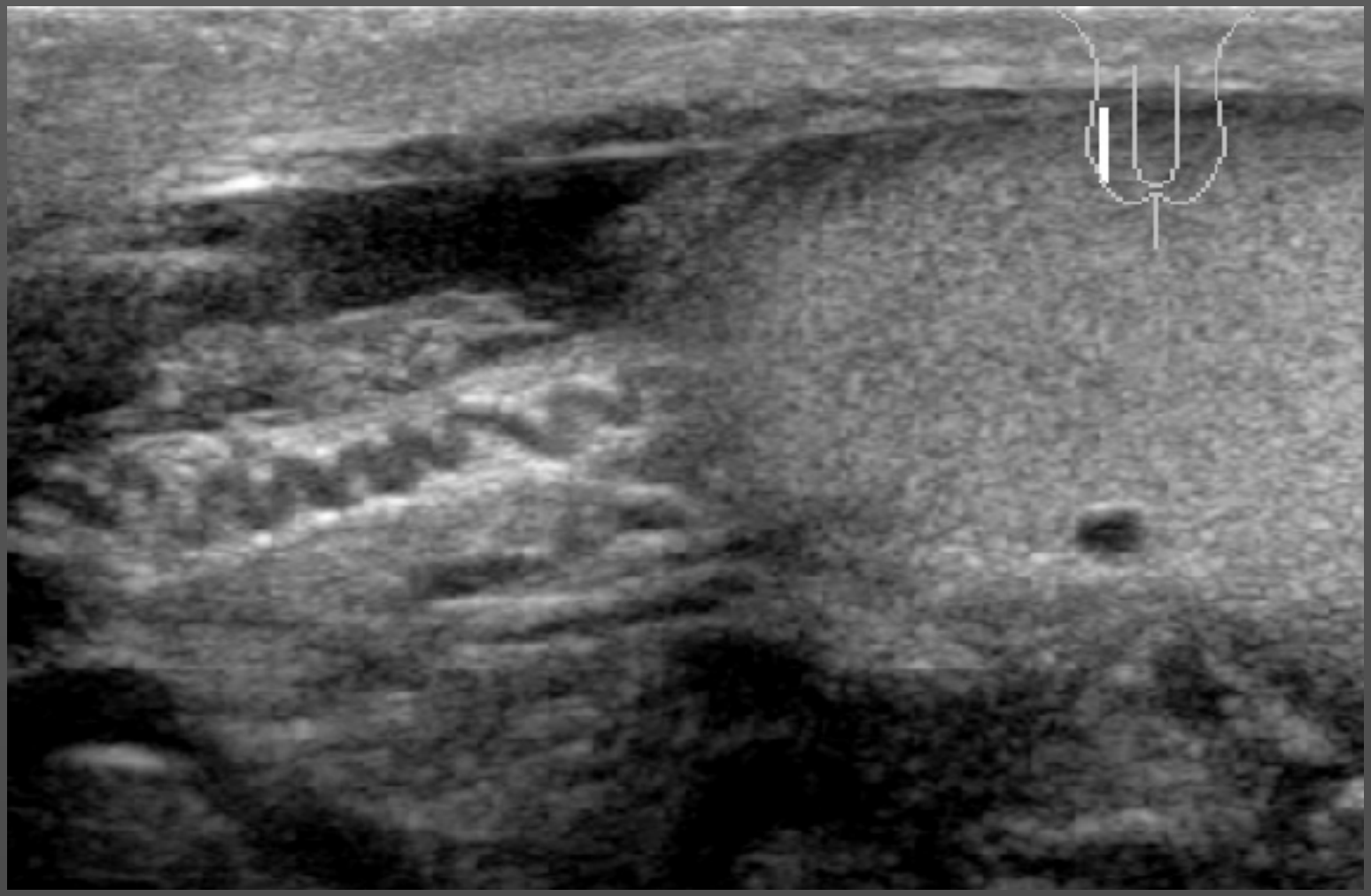



DURS
Danish Society of Urroradiology

Scrotum

Extratesticular mass: Benign

Intratesticular mass: Malignant

- nearly allways

But palpation is not always precise



DURS
Danish Society of Ultrasonology

Scrotum

=> Ultrasound examination



DURS
Danish Society of Ultrasonology

Scrotum

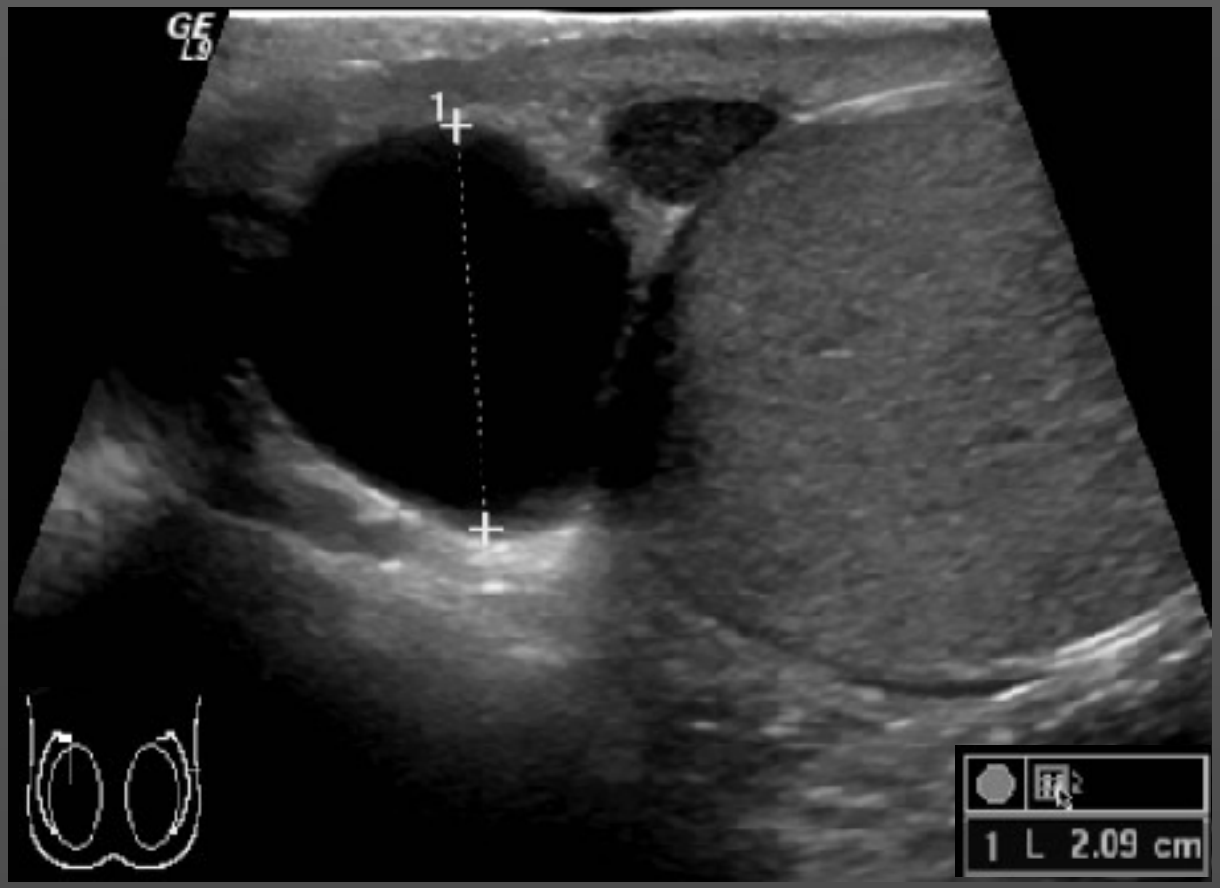

31 year.

No symptoms.

Palpable mass, uncertain if it is intratesticular.

Spermatocele

Scrotum

Let us zoom in to the testis

Scrotum

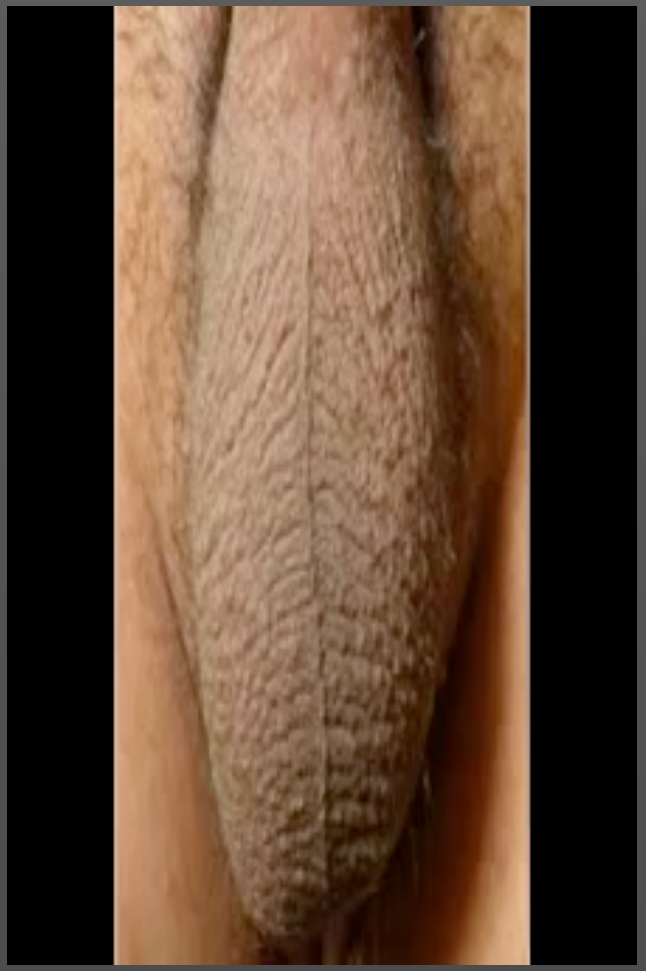

Let us zoom in to the testis

Testis cancer – epidemiology

Incidence

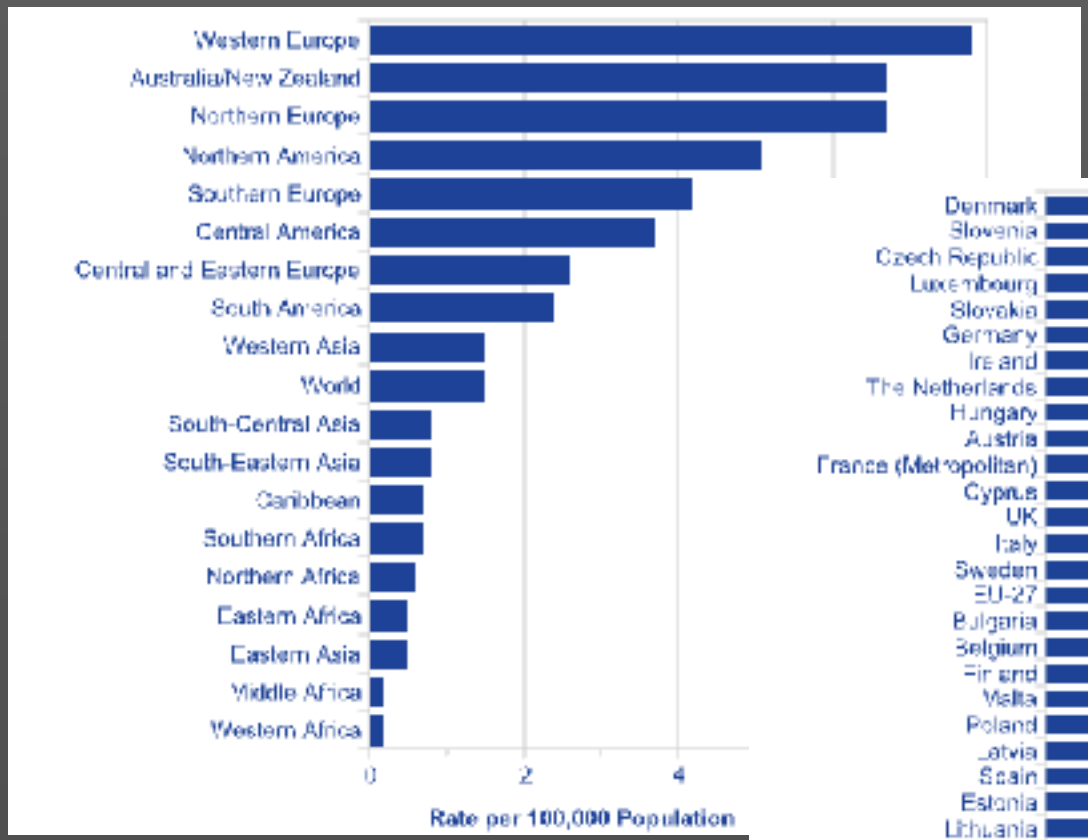

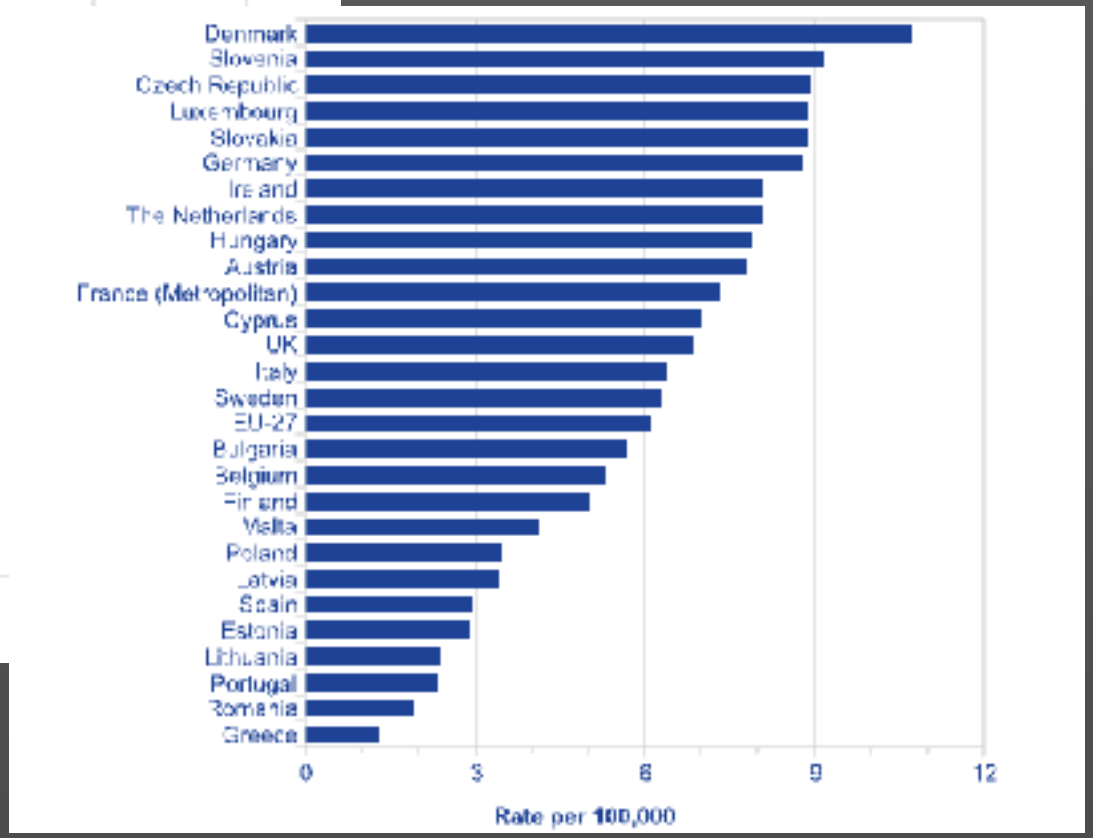

10 : 100.000 per year

Testis cancer – epidemiology

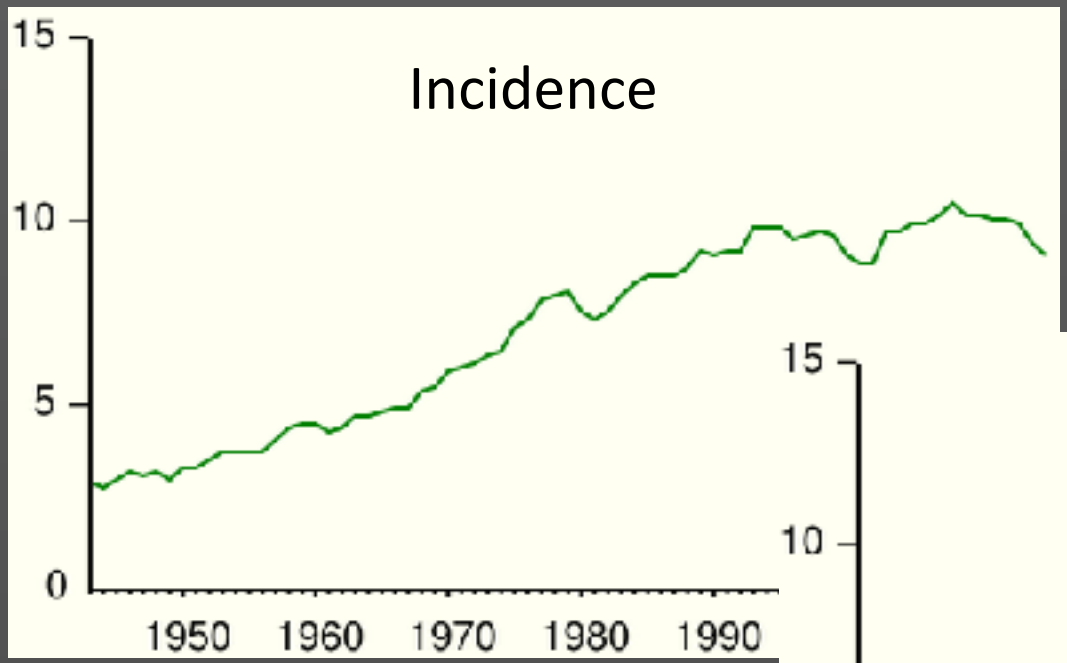

Death rate

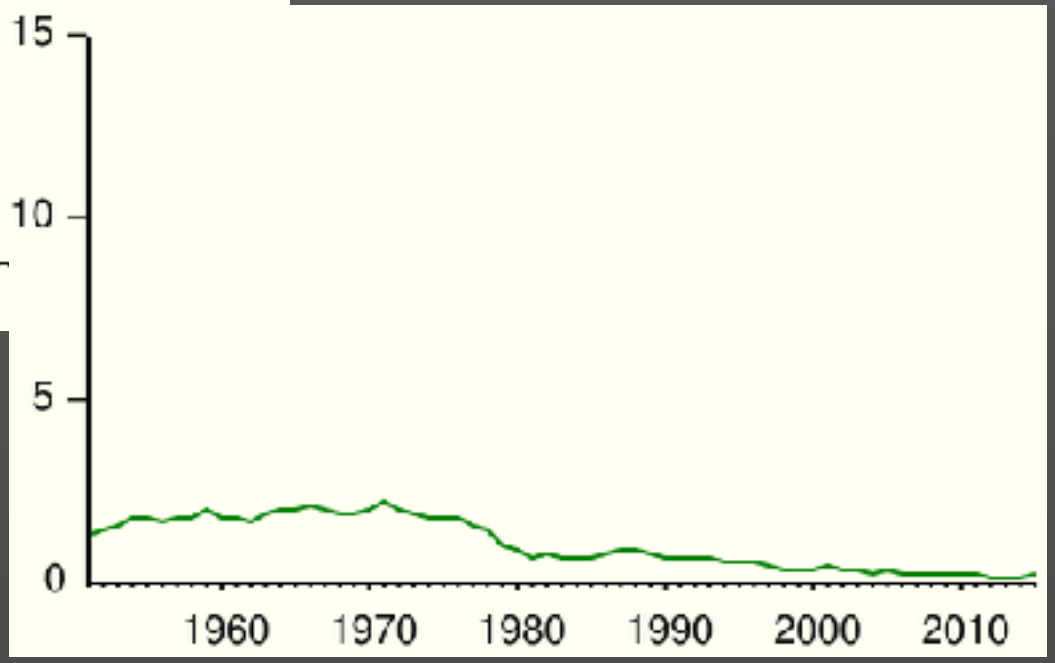

0,2 : 100.000 per year

Testis cancer – epidemiology

5 year survival (all stages):

97% (95 – 100)

Why worry about early diagnosis?



DURS
Danish Society of Urroradiology

Ultrasound of malignant testicular lesions



DURS
Danish Society of Ultrasonology

Testis pathology

- Neoplasm
  - Malignant
  - Benign
- Cyst
- Infection
- Vascular
  - Torsio
  - Infarction
  - Atrophy



DURS
Danish Society of Ultrasonology

Testis pathology

- Neoplasm
  - Malignant
  - Benign
- Cyst
- Infection
- Vascular
  - Torsio
  - Infarction
  - Atrophy



DURS
Danish Society of Uroradiology

Testis pathology

Neoplasm (all ages)

- Malignant 90%
- Benign 10%



DURS
Danish Society of Urroradiology

Testis pathology

Neoplasm

- Germ cell 90%
  - Seminoma 50%
  - Non-seminoma 50%
- Stroma (Sertoli -, Leyding -) 5%
- Other (Lymphoma, metatastasis, - -) 5%



DURS
Danish Society of Urroradiology

Testis pathology

- Neoplasm
  - Malignant
  - Benign
- Cyst
- Infection
- Vascular
  - Torsio
  - Infarction
  - Atrophy



DURS
Danish Society of Ultrasonology

Testis ultrasound

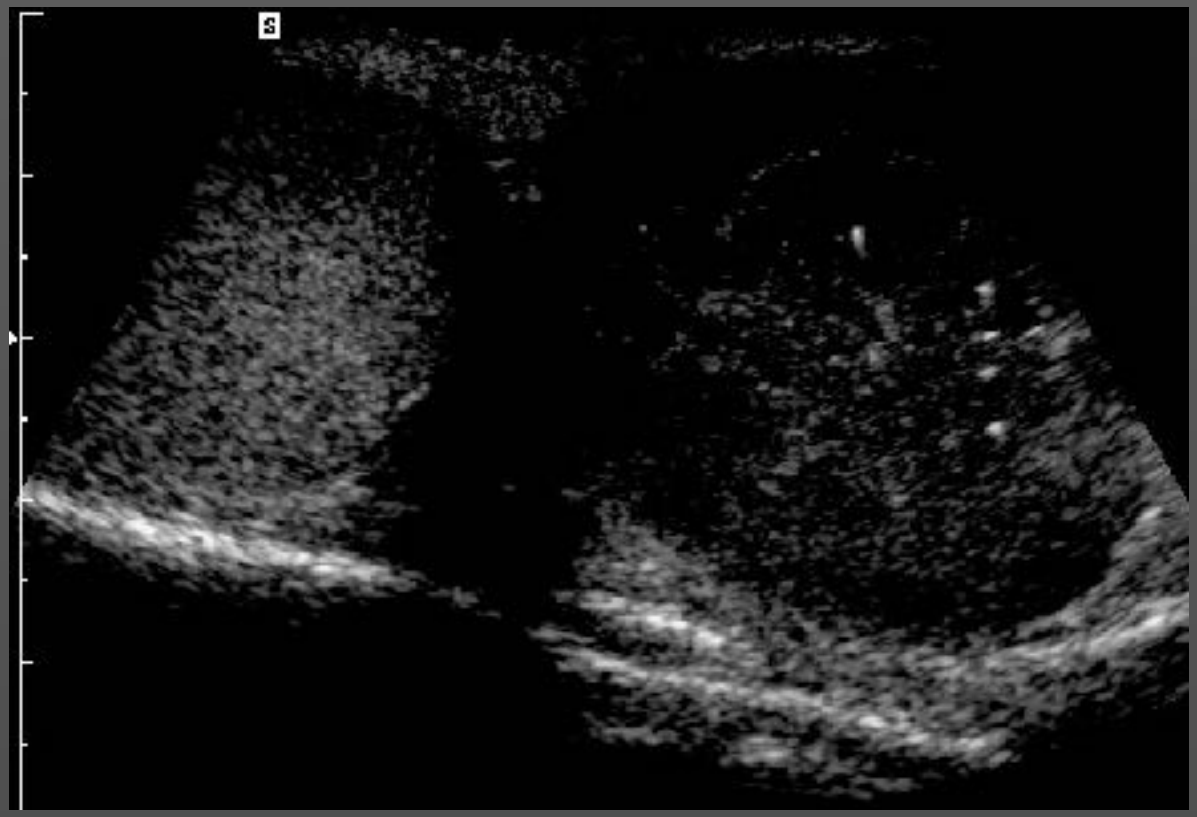

34 year.

No symptoms.

Palpable mass.

Testis ultrasound

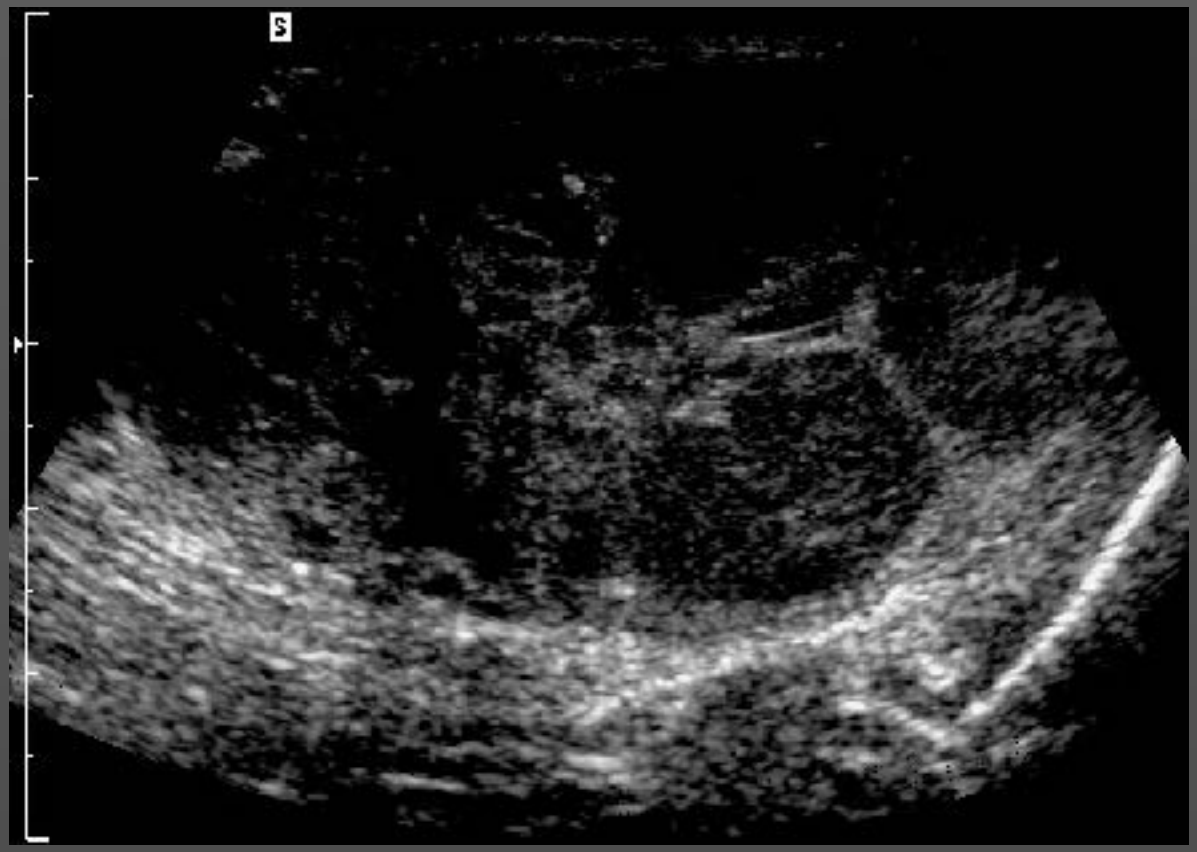

34 year.

No symptoms.

Palpable mass.

US: Testis tumour

Pathology: Seminoma

Testis ultrasound

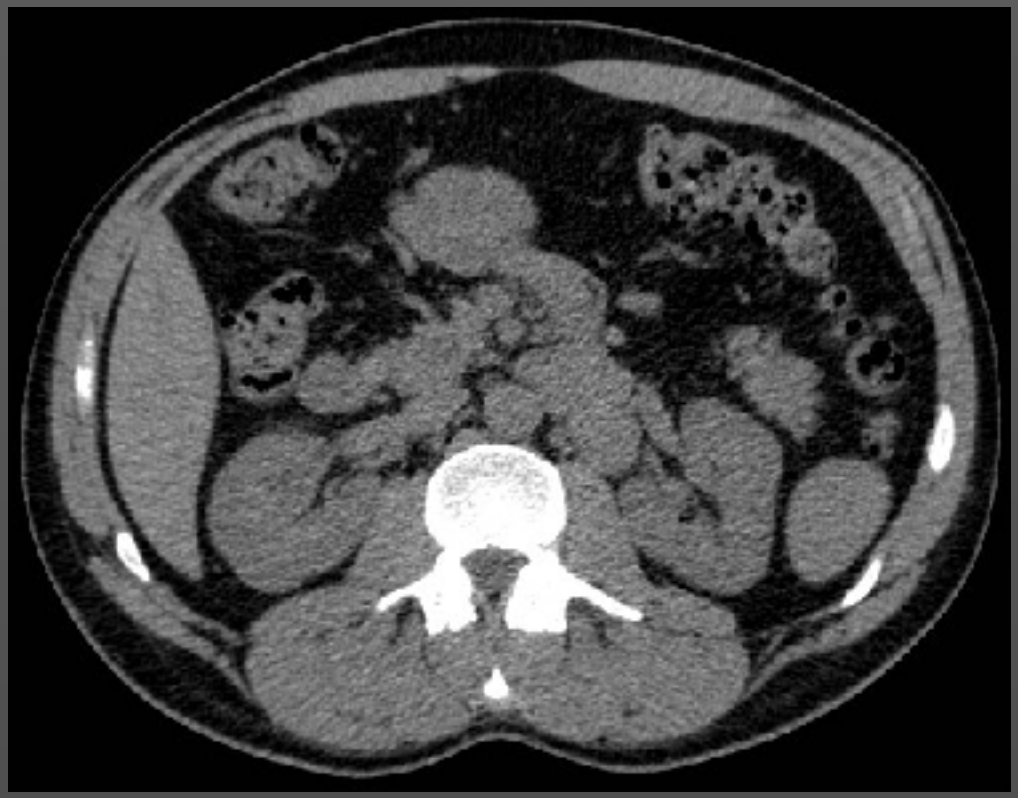

28 year.

Left flank colic pain.

Ureteral stone?

CT: No stones. Suspicious retroperitoneal lymph nodes.

Testis cancer?

Testis ultrasound

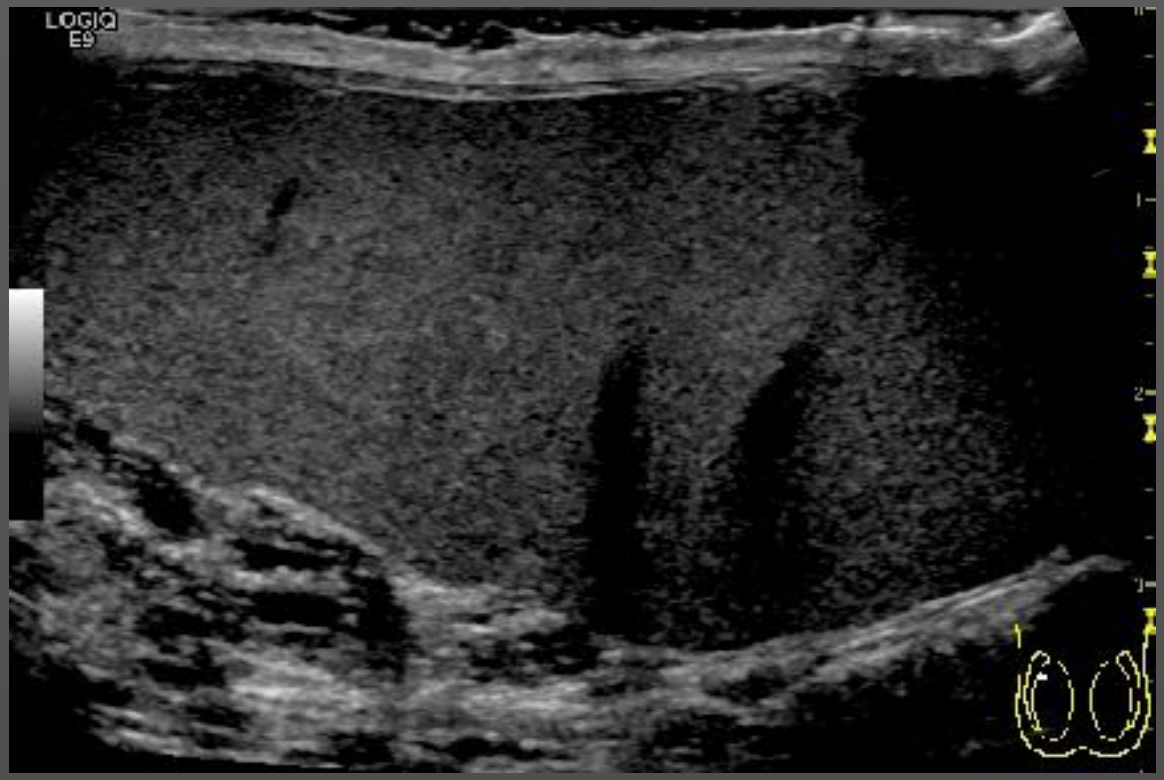

28 year.

Left flank colic pain.

Ureteral stone?

Left testis smaller,

no palpable mass.



DURS
Danish Society of Urroradiology

Testis ultrasound

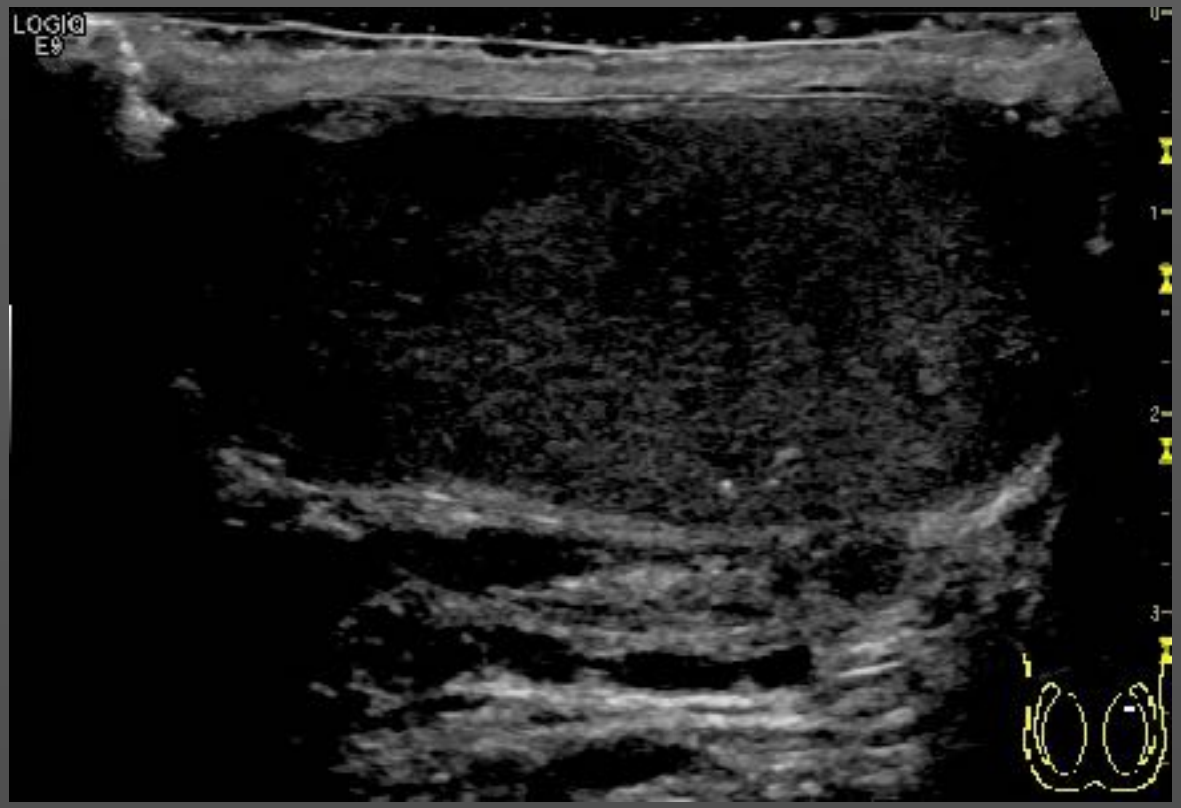

28 year.

Left flank colic pain.

Ureteral stone?

Left testis smaller,

no palpable mass.

Danish Society of Urroradiology

Testis ultrasound

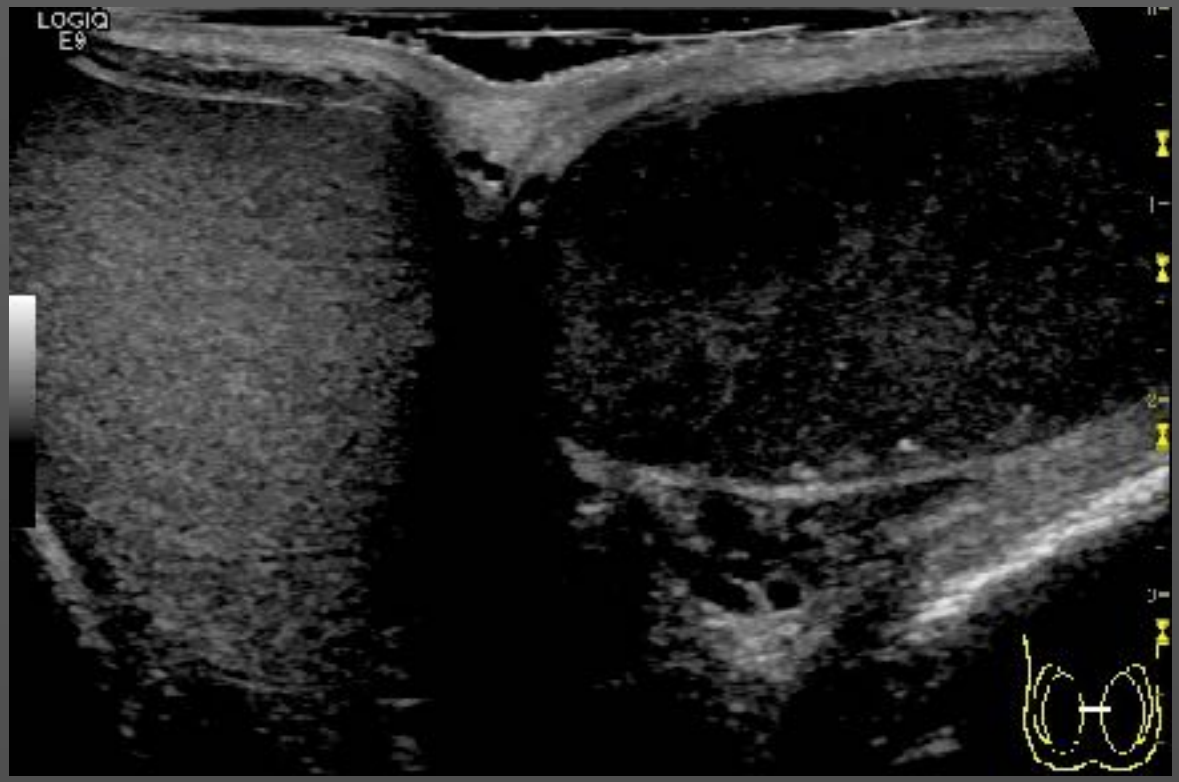

28 year.

Left flank colic pain.

Ureteral stone?

Left testis smaller,

no palpable mass.



DURS
Danish Society of Urroradiology

Testis ultrasound

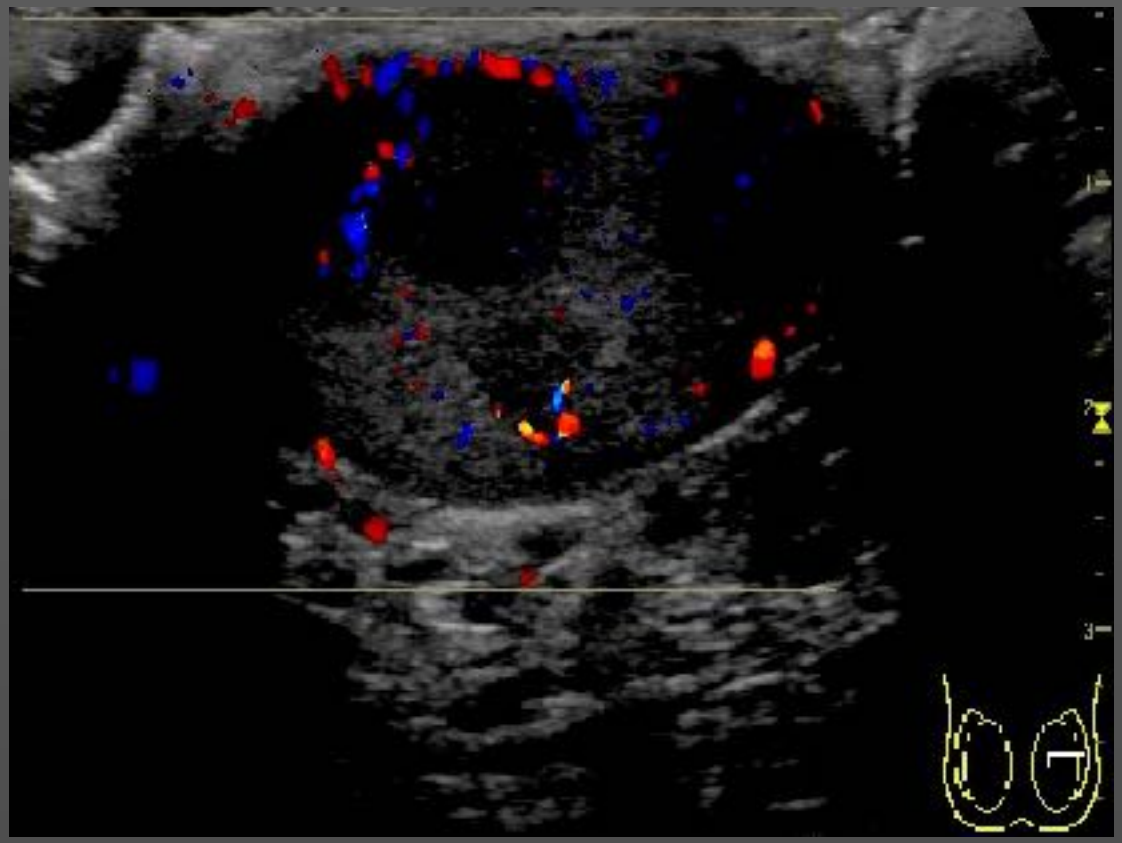

28 year.

Left flank colic pain.

Ureteral stone?

Left testis smaller,

no palpable mass.

US: Testis tumour

Pathology: Non-seminomatous mixed germ cell tumours

Testis ultrasound

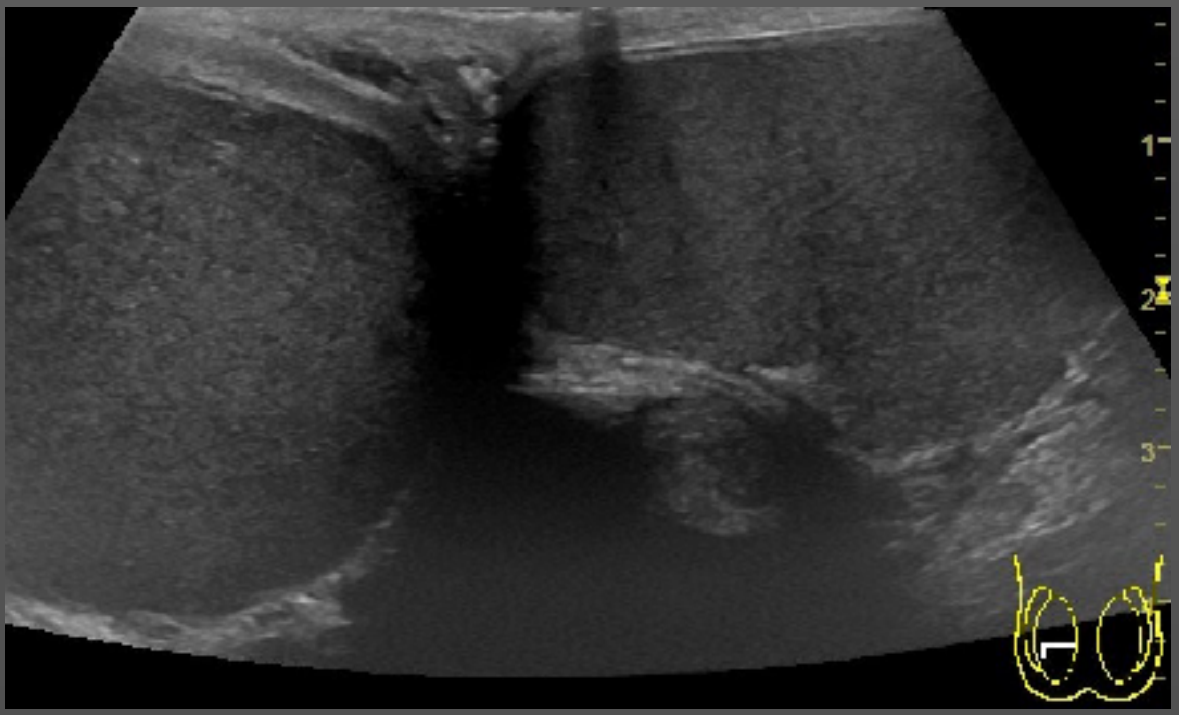

49 year.

Growing right testis.

No other symptoms.

US ref.: Hydrocele?

DURS
Danish Society of Ultrasonology

Testis ultrasound

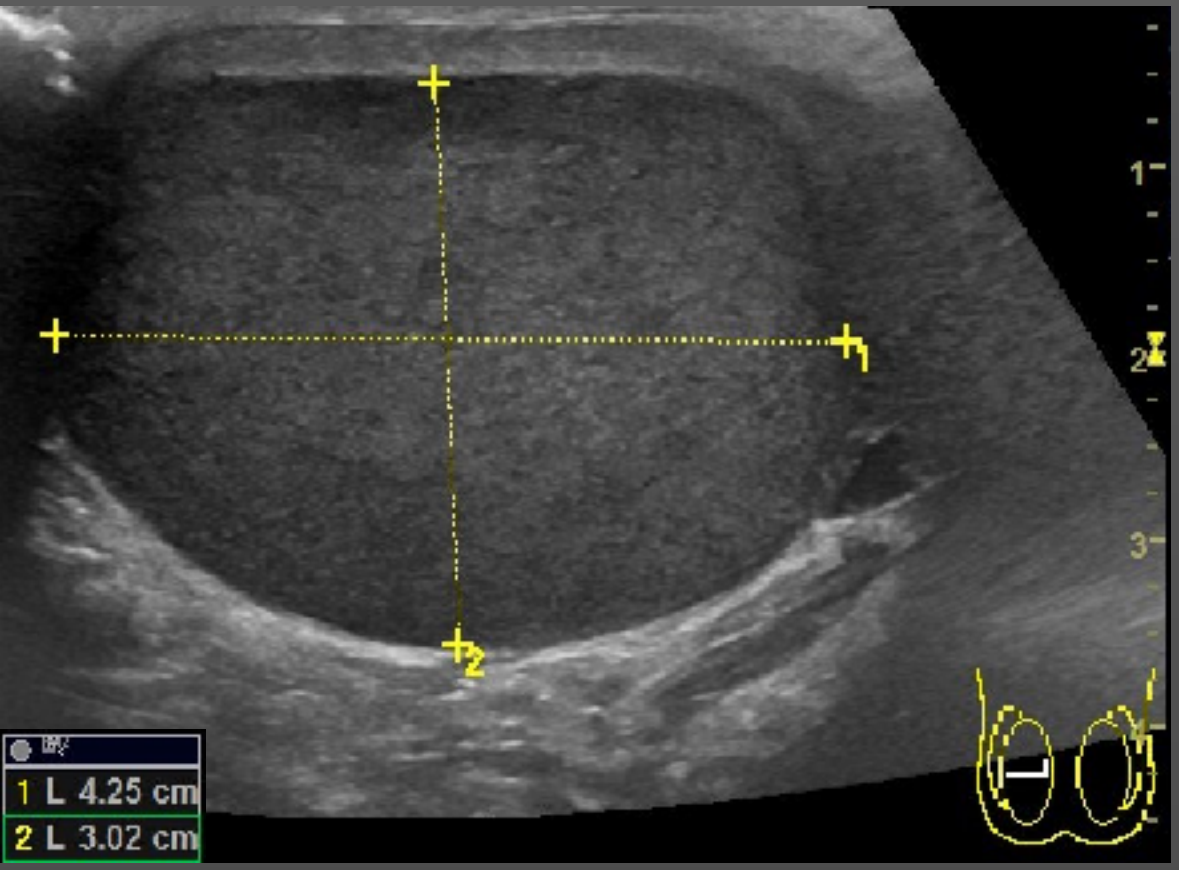

49 year.

Growing right testis.

No other symptoms.

US ref.: Hydrocele?

Testis ultrasound

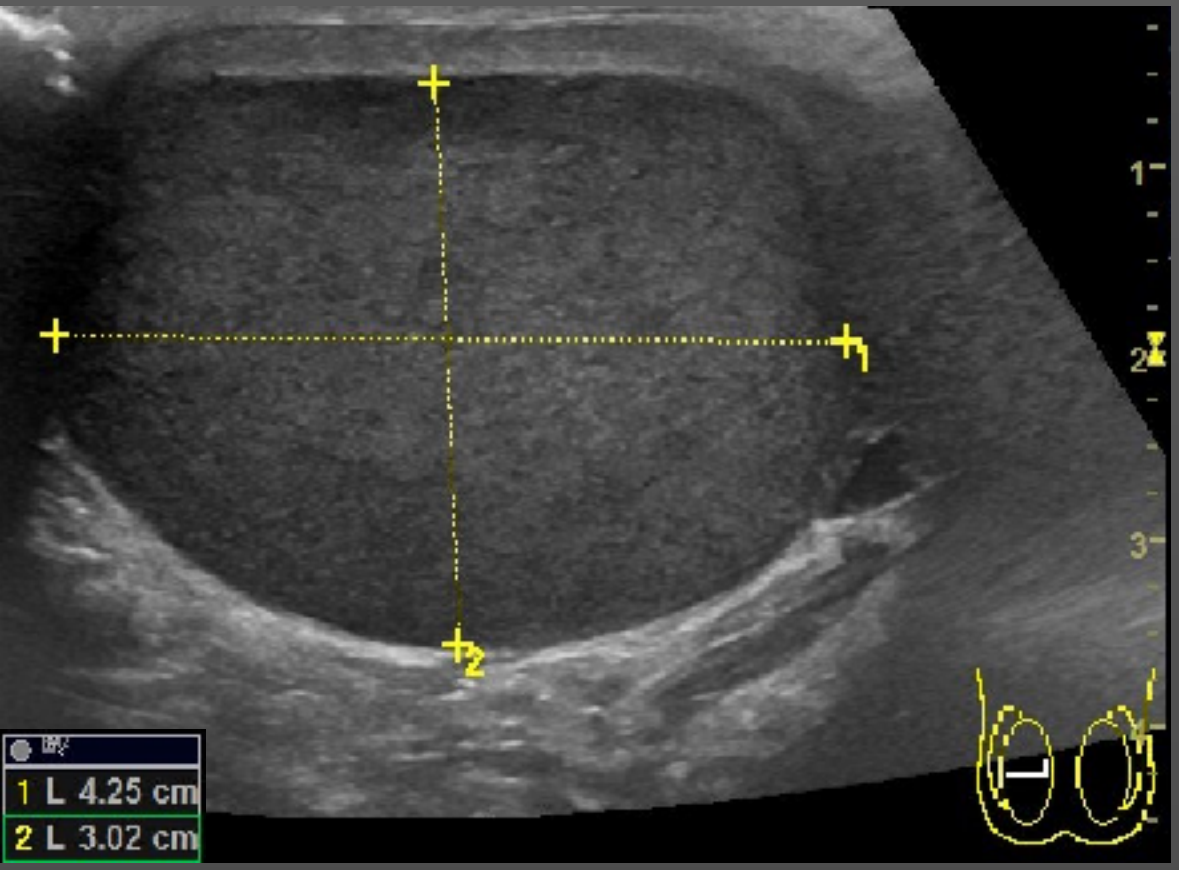

49 year.

Growing right testis.

No other symptoms.

US ref.: Hydrocele?

US: slightly enlarged right epididymis.

Slightly enlarged right testis.



DURS
Danish Society of Ultrasonology

Testis ultrasound

One year later:

Growing right testis.

Surgery.

Testis 7,5 x 5 cm

Pathology:

Mixed germ cell tumor.

49 year.

Growing right testis.

No other symptoms.

US ref.: Hydrocele?

US: slightly enlarged right epididymis.

Slightly enlarged right testis.



DURS
Danish Society of Ultrasonology

Testis ultrasound

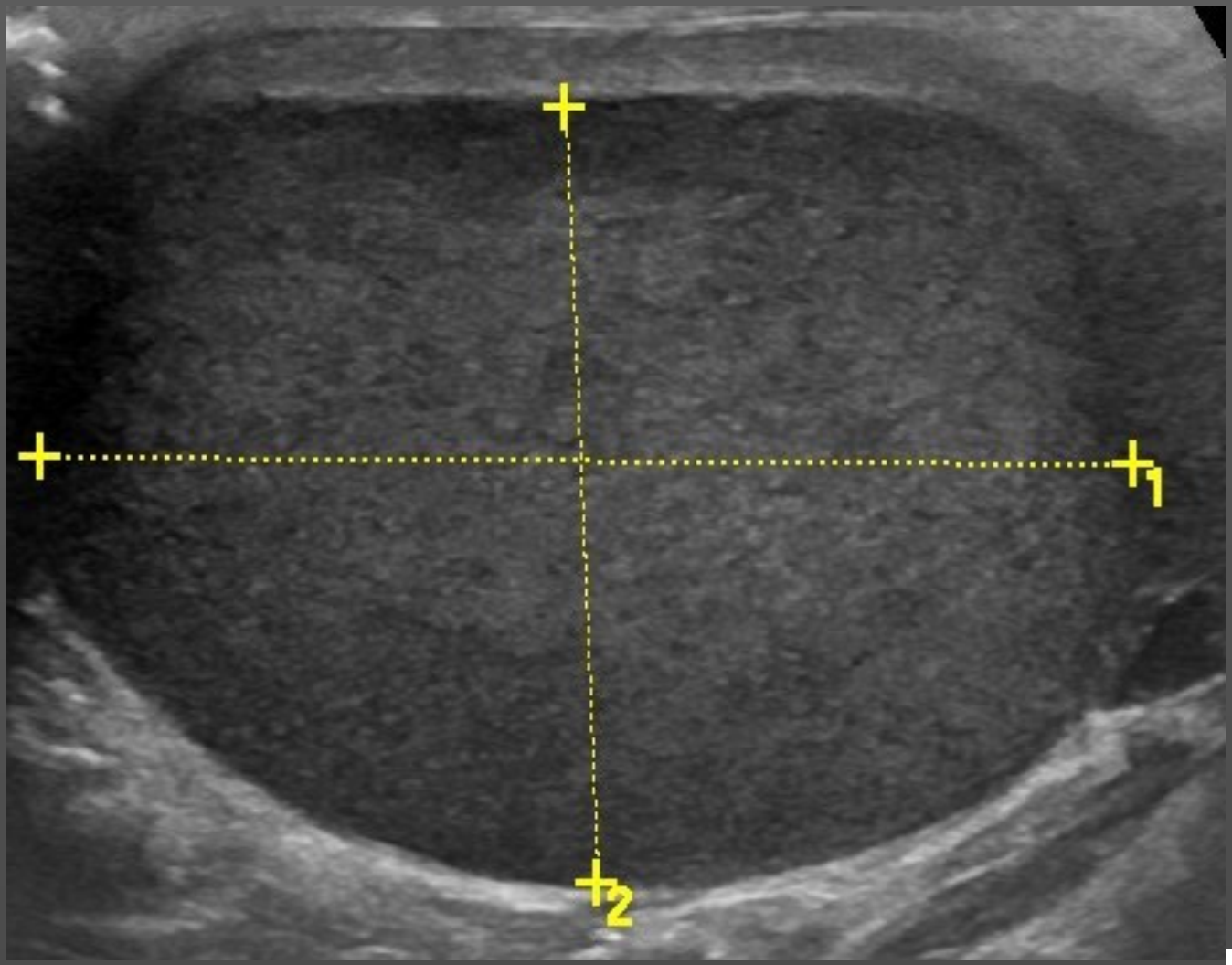

Testis ultrasound

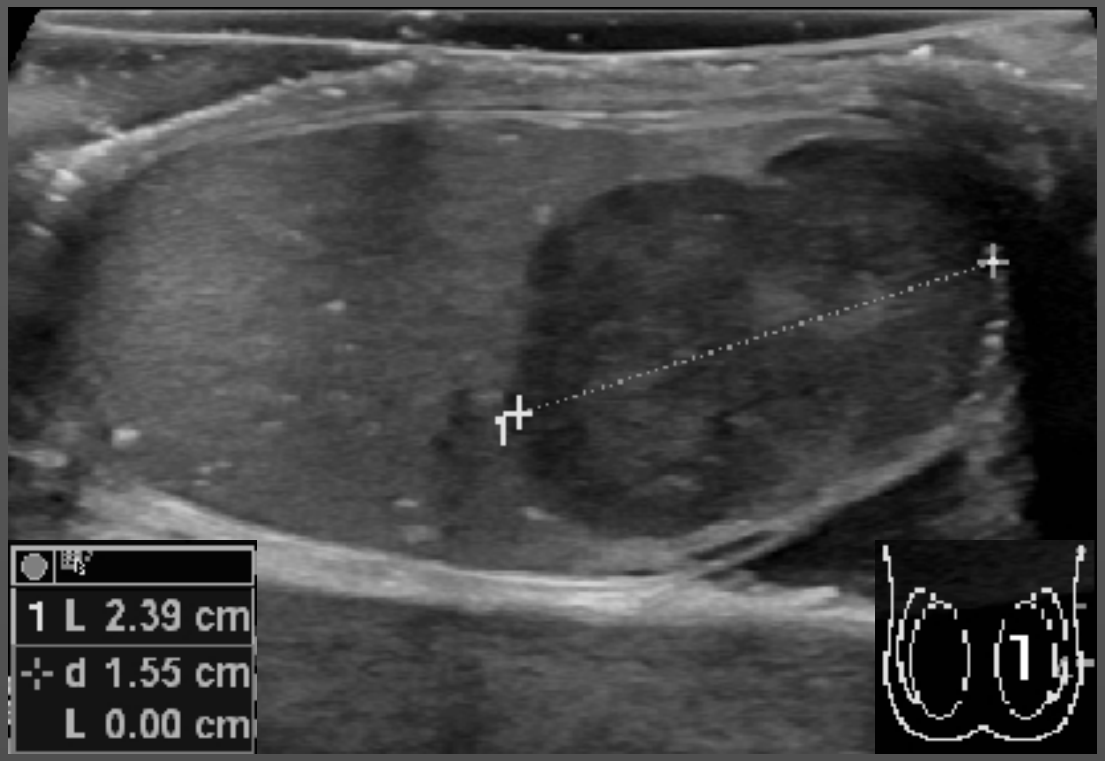

2012. 26 year.

Growing left testis.

Palpable mass.

Testis ultrasound

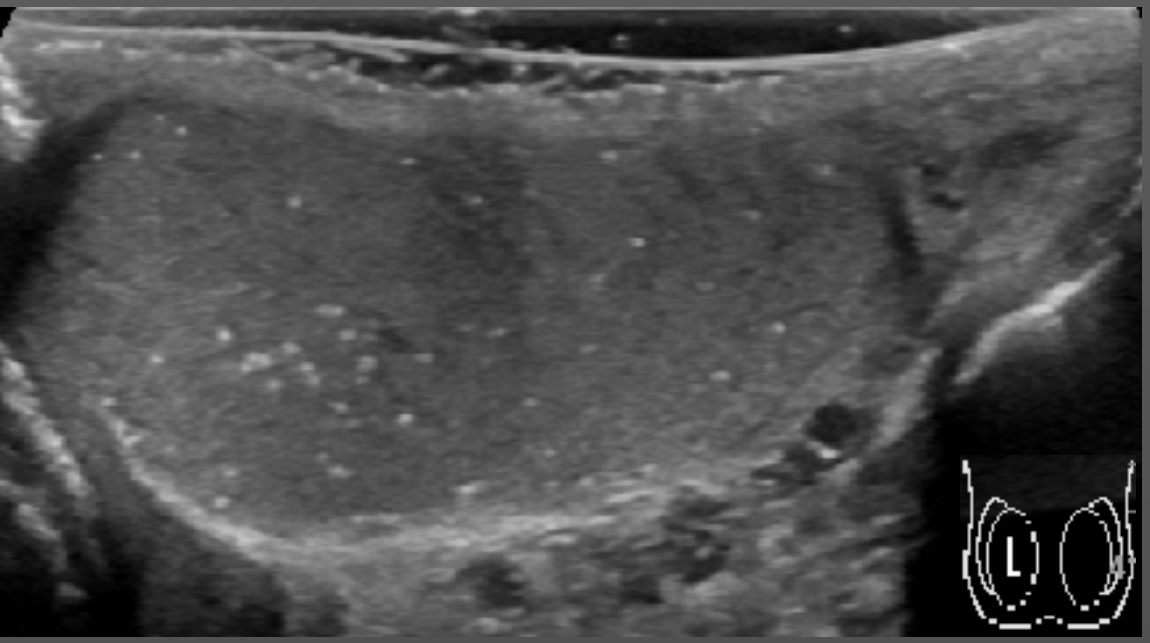

2012. 26 year.

Growing left testis.

Palpable mass.

Testis ultrasound

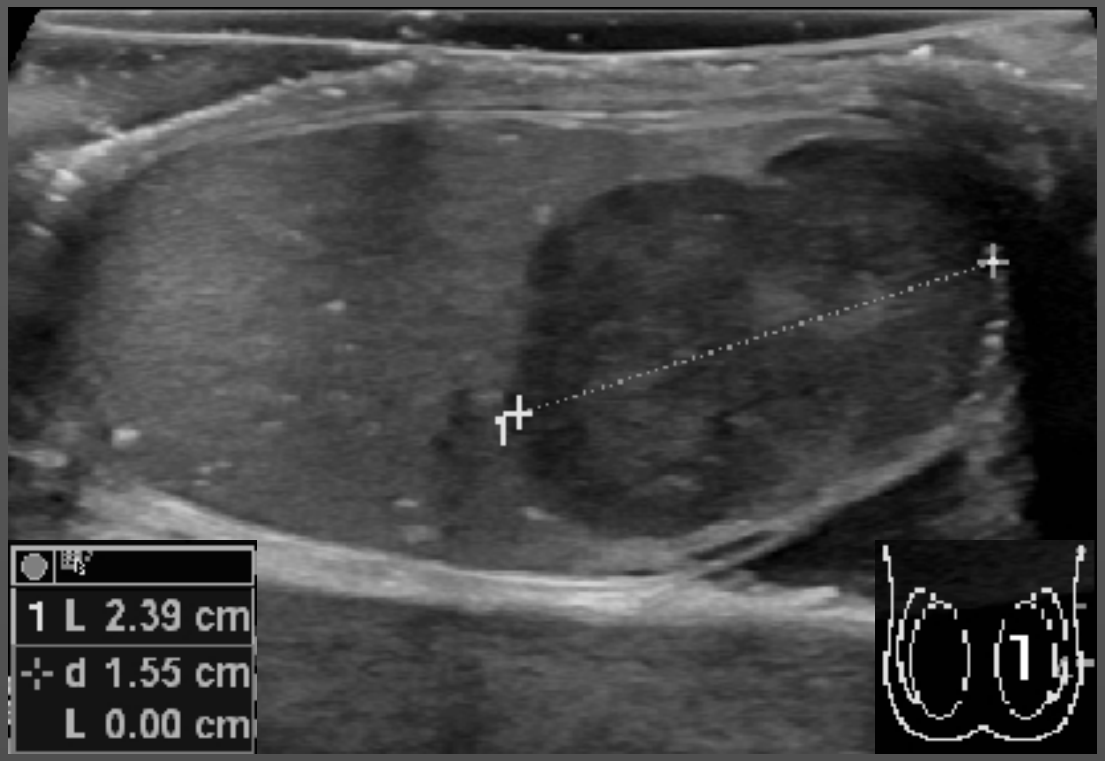

2012. 26 year.

Growing left testis.

Palpable mass.

US: Left testis tumour. Bilat. high-echogenic changes, microlithiasis.

Pathology: Seminoma left testis

Carcinoma in situ right testis

Testis ultrasound

2012. 26 year.

No metastasis. No chemotherapy.

Scrotum radiation treatment.

Follow-up:
CT and US

2012. 26 year.

Growing left testis.

Palpable mass.

US: Left testis tumour. Bilat. high- echogenic changes, microlithiasis.

Pathology: Seminoma left testis

Carcinoma in situ right testis



DURS
Danish Society of Uroradiology

Testis ultrasound

2012. 26 year.

No metastasis. No chemotherapy.

Scrotum radiation treatment.

Follow-up:
CT and US

Until 2017 no relapse.

Microlithiasis in right testis.

Pathology: Seminoma left testis

Carcinoma in situ right testis



DURS
Danish Society of Uroradiology

Testis ultrasound

2012. 26 year.

No metastasis. No chemotherapy.

Scrotum radiation treatment.

Follow-up:
CT and US

Until 2017 no relapse.

Microlithiasis in right testis.

2018:



DURS
Danish Society of Ultrasonology

Testis ultrasound

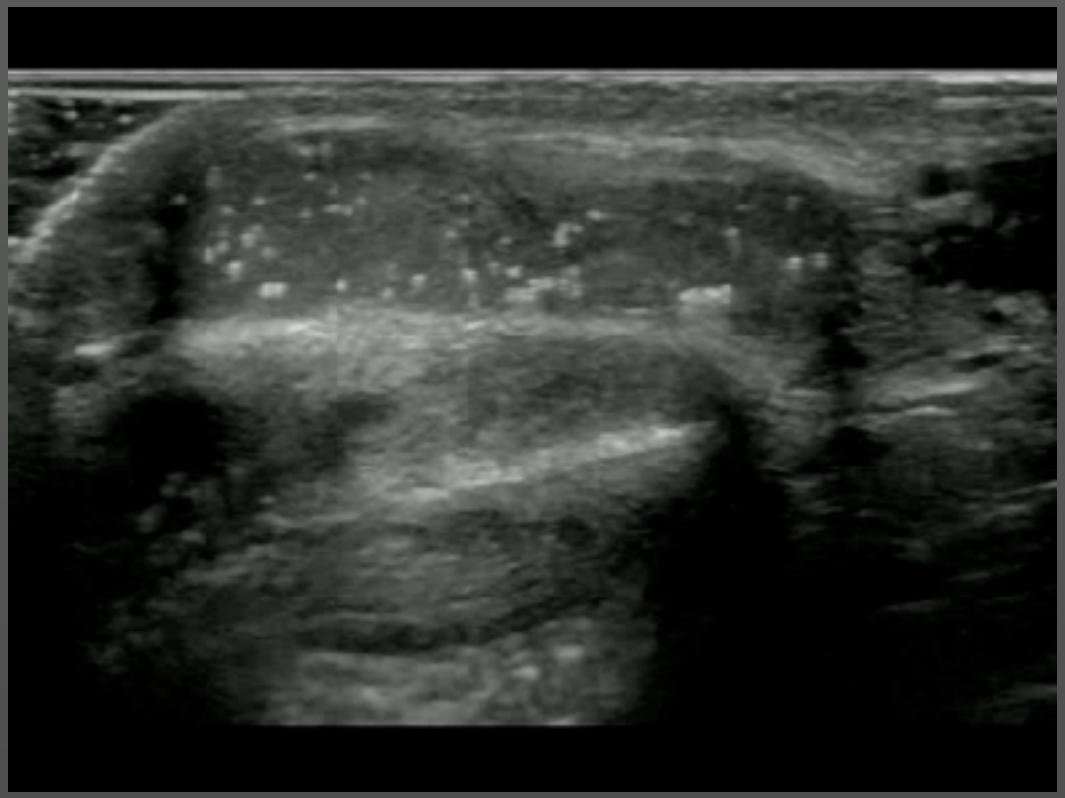

Until 2017 no relapse.

Microlithiasis in right testis.

2018:

Testis ultrasound

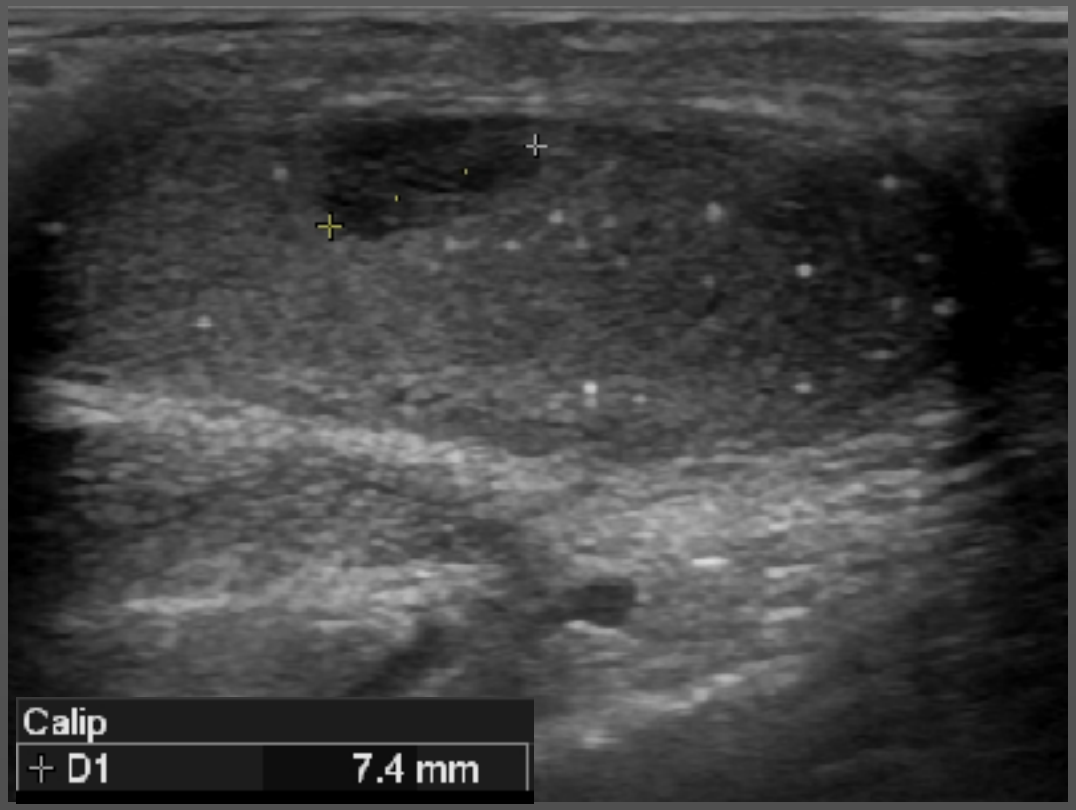

Until 2017 no relapse.

Microlithiasis in right testis.

2018: 7 mm new tumour in right testis.



DURS
Danish Society of Urroradiology

Testis ultrasound

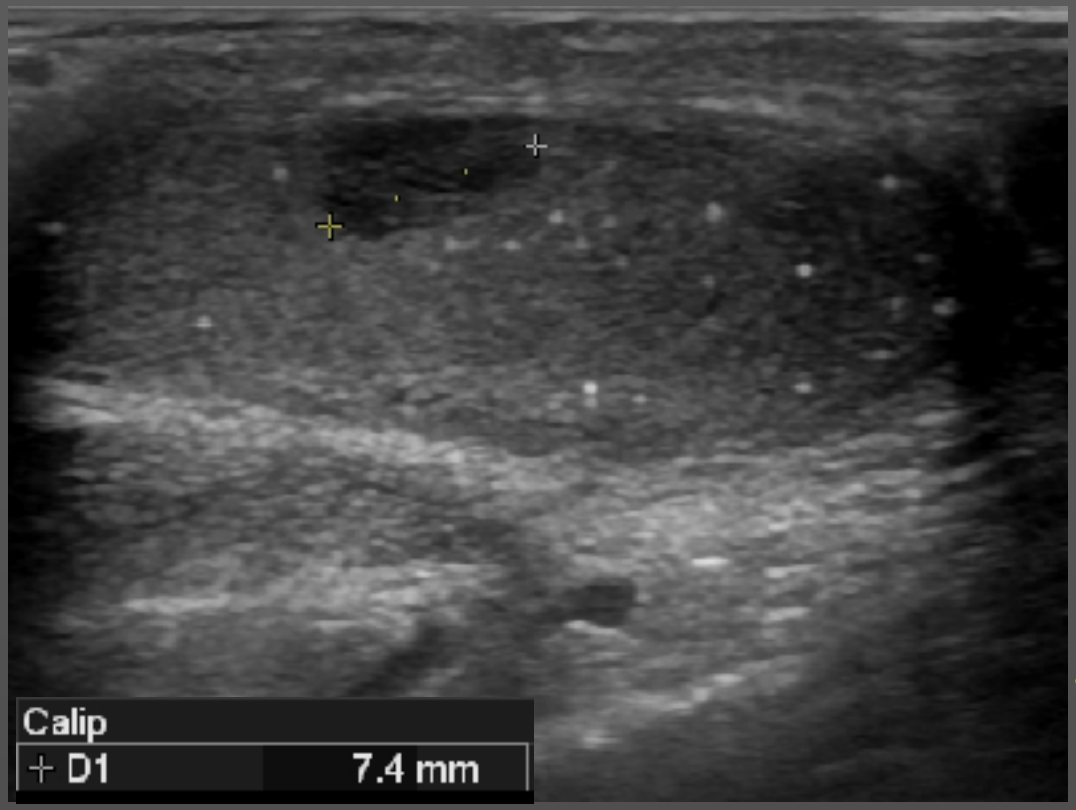

Until 2017 no relapse.

Microlithiasis in right testis.

2018: 7 mm new tumour in right testis.

Testis sparing surgery

Pathology: Seminoma right testis

DURS
Danish Society of Urroradiology

Testis ultrasound

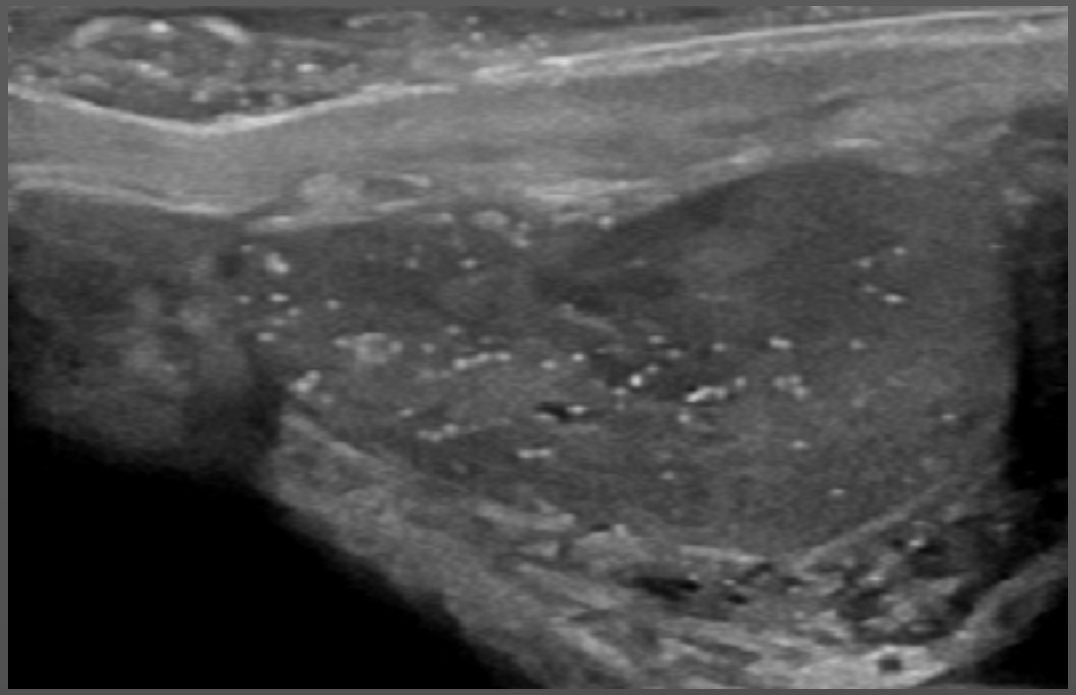

2018:

One week after testis sparing surgery:



Testis ultrasound

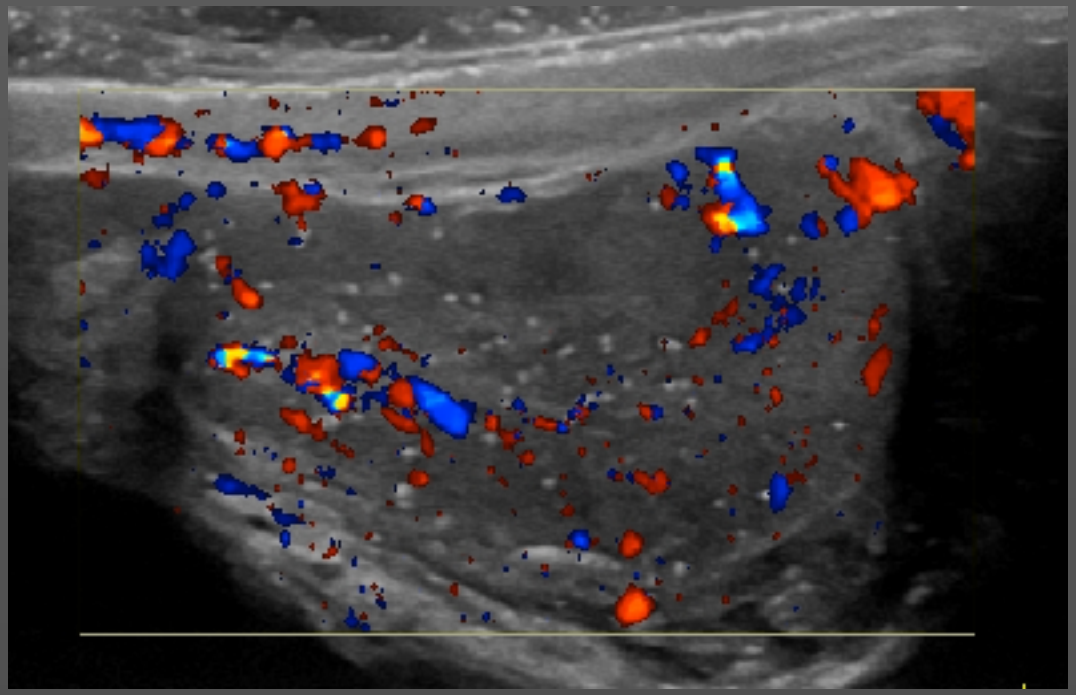

2018:

One week after testis sparing surgery:

Testis ultrasound

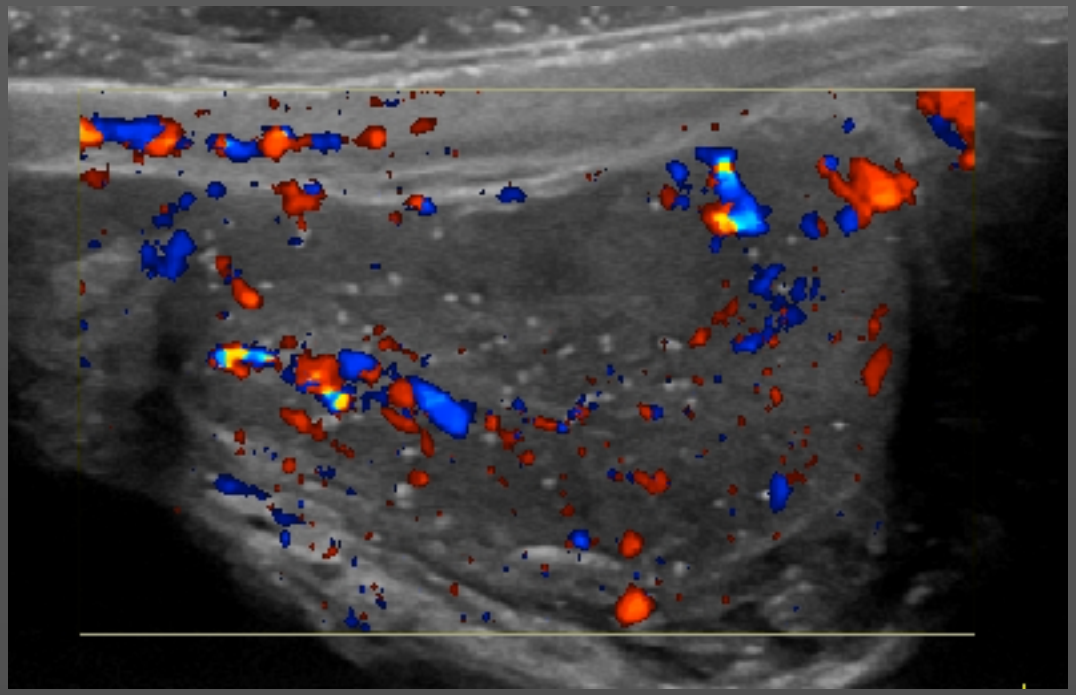

2018:

One week after testis sparing surgery:

US: Vital testis after testis sparing surgery

Testis ultrasound

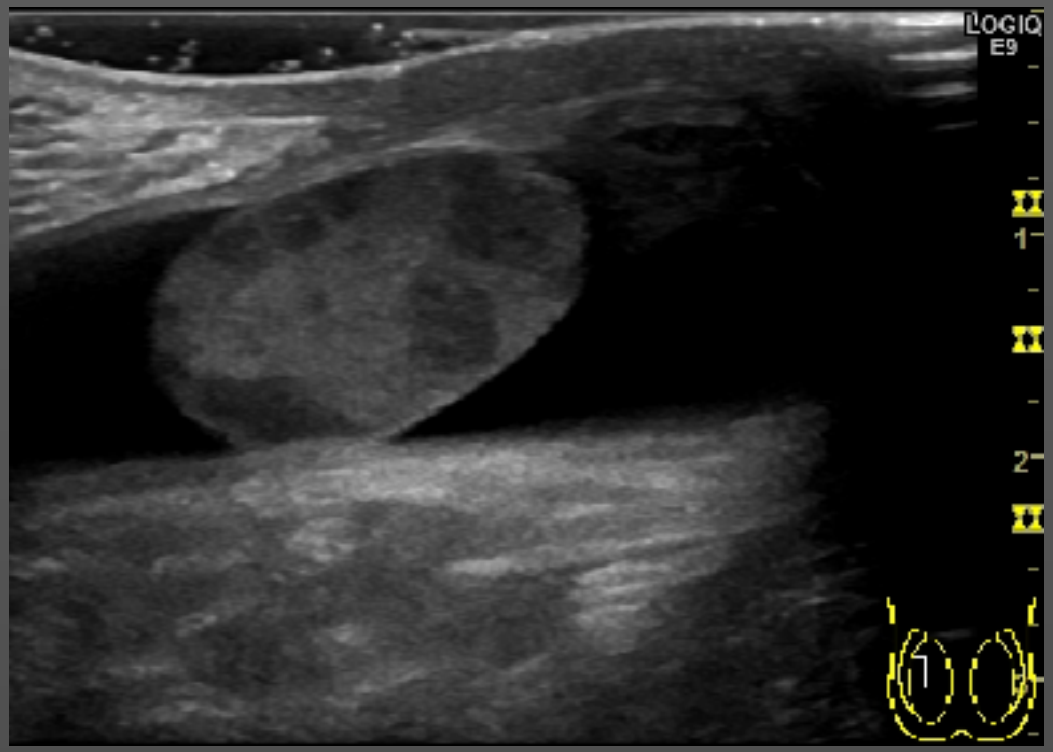

2 month old boy.

Growing right side of scrotum. Hydrocele?

Testis ultrasound

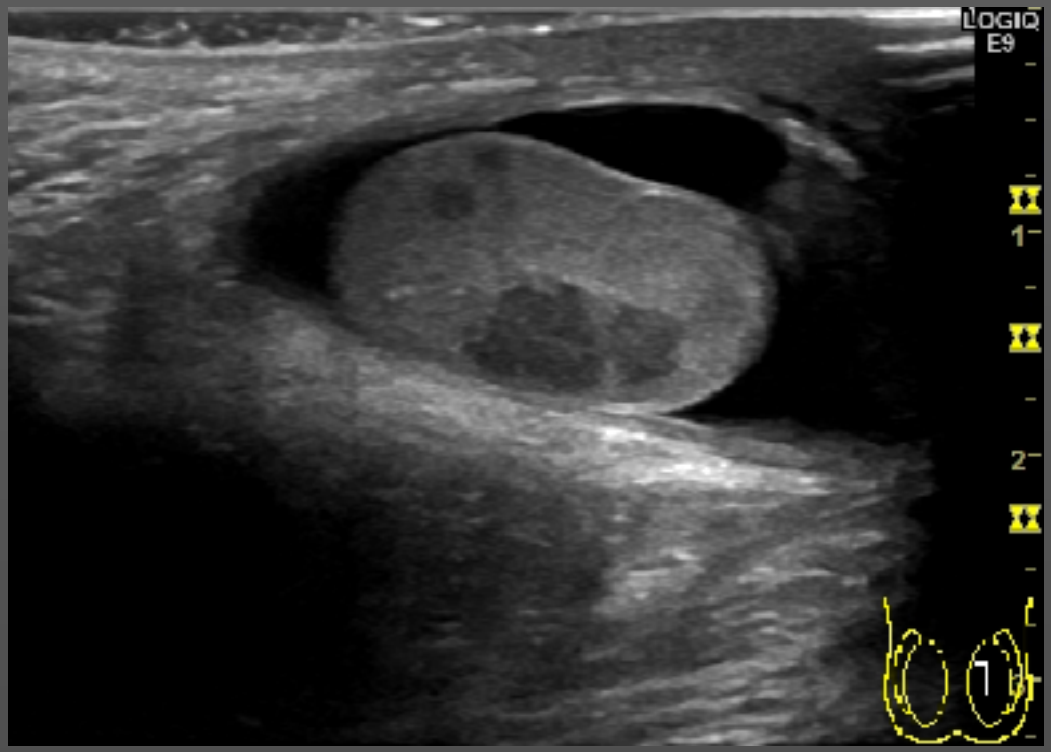

2 month old boy.

Growing right side of scrotum. Hydrocele?

US: Multiple tumours in both testes.



DURS
Danish Society of Ultrasonology

Testis ultrasound

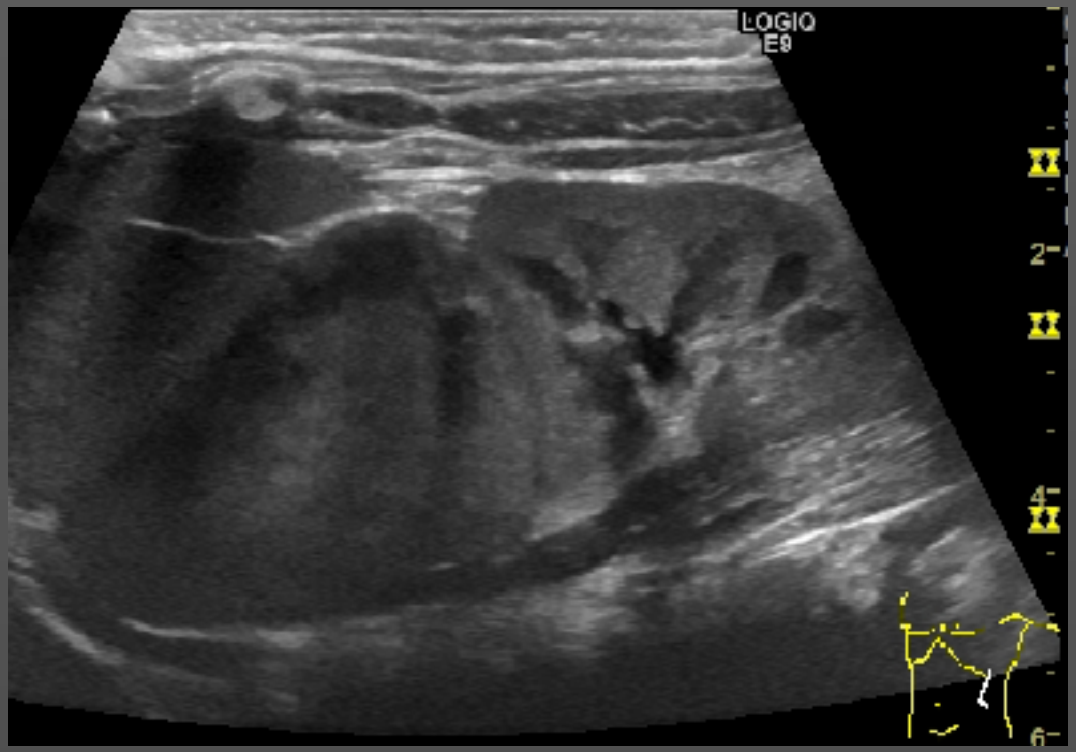

2 month old boy.

Further investigation:

4 cm tumour in left adrenal gland.



DURS
Danish Society of Ultrasonology

Testis ultrasound

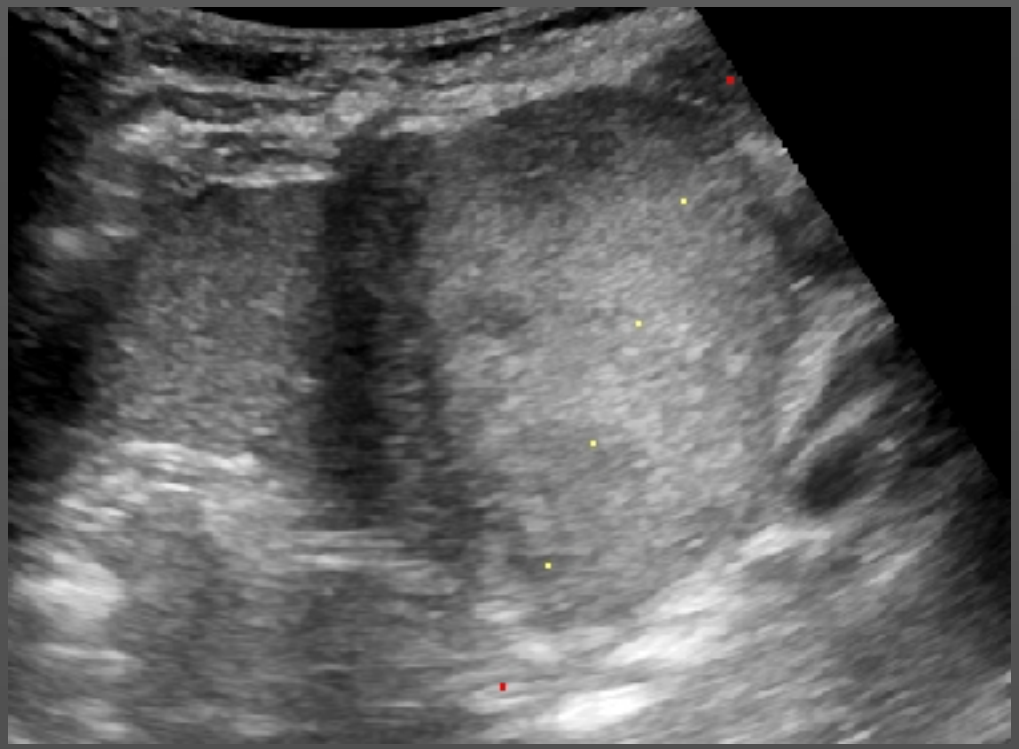

2 month old boy.

Further investigation:

4 cm tumour in left adrenal gland.

Pathology: Neuroblastoma

(with metastases)

Testis ultrasound

Chemotherapy and surgery.

Follow-up: MRI and US

2 month old boy.

Further investigation:

4 cm tumour in left adrenal gland.

Pathology: Neuroblastoma (with metastases)



DURS
Danish Society of Ultrasonology

Testis ultrasound

After 3 years:

No relapse.



DURS
Danish Society of Ultrasonology

Testis ultrasound

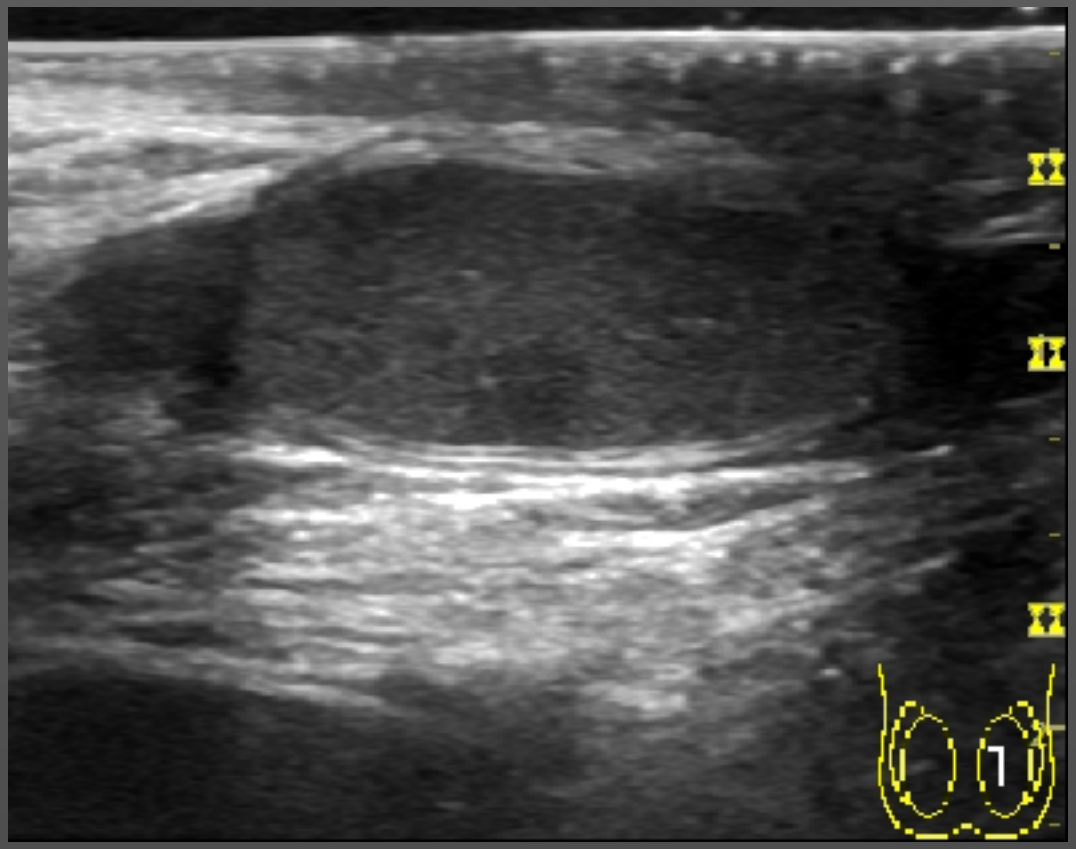

After 3 years:

No relapse.

US: Unchanged very discrete changes in both testes.

Testis ultrasound

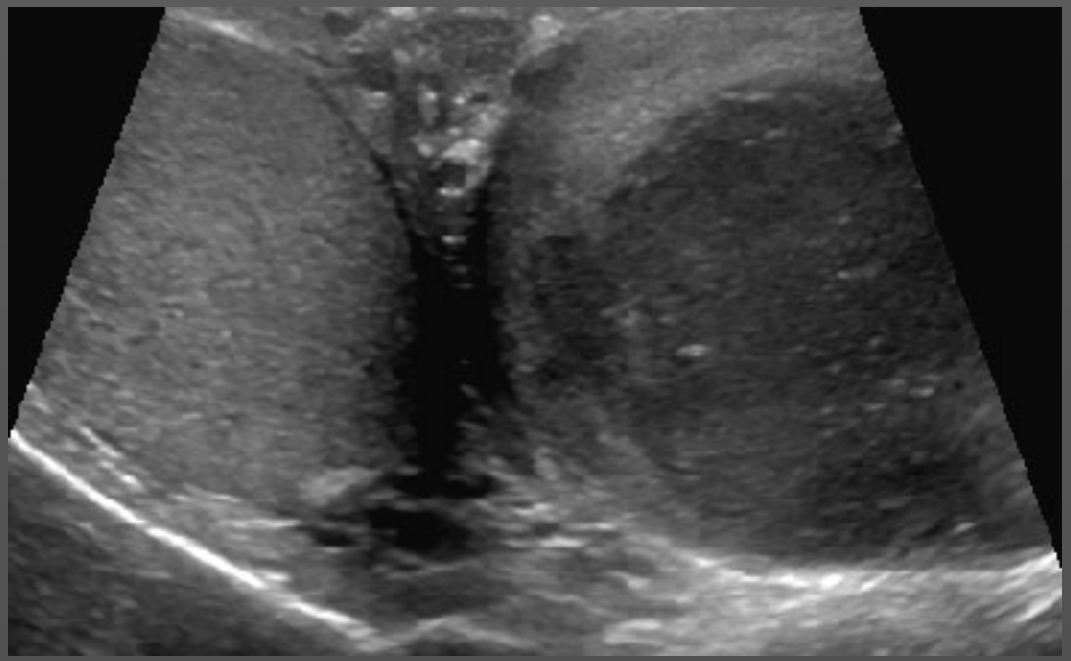

73 year.

Growing left testis.

No other symptoms.

Palpable mass.

Testis ultrasound

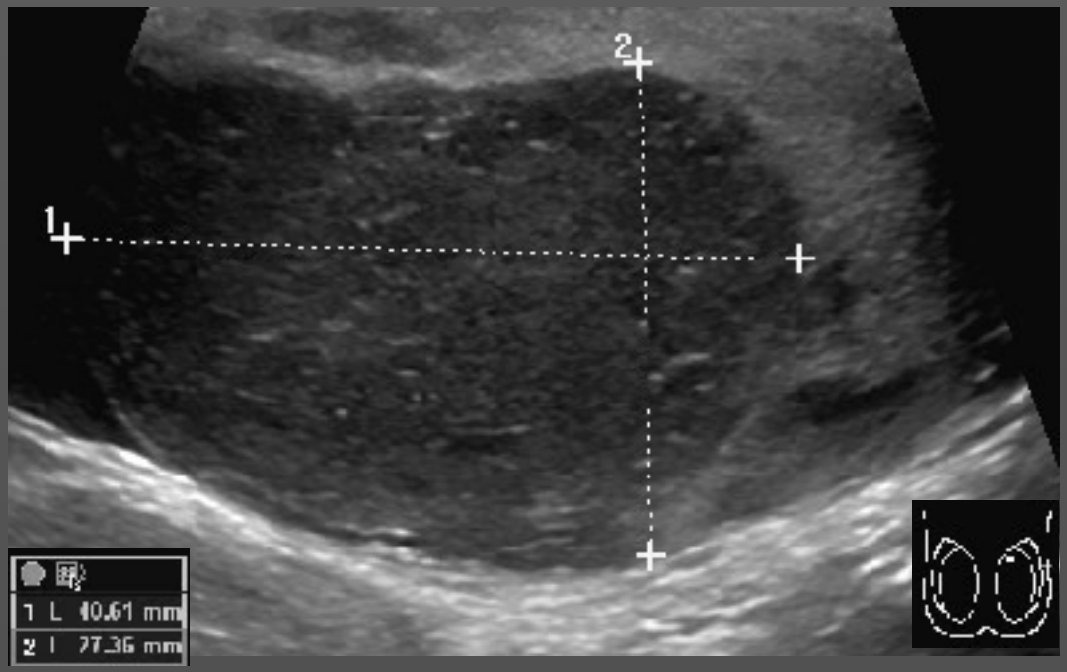

73 year.

Growing left testis.

No other symptoms.

Palpable mass.

Testis ultrasound

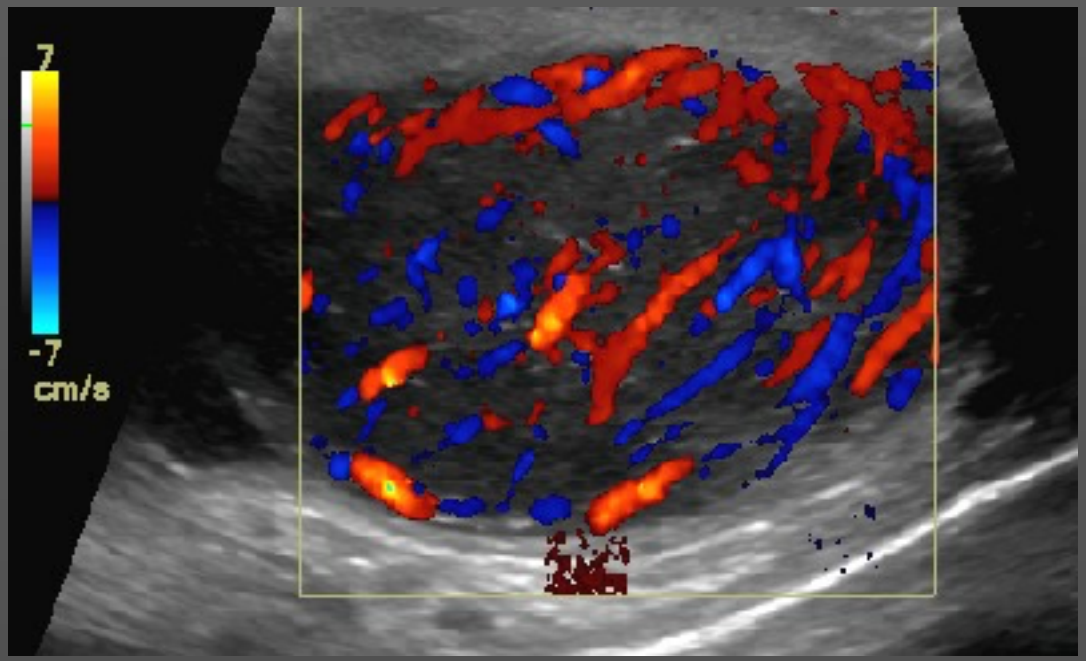

73 year.

Growing left testis.

No other symptoms.

Palpable mass.

US: Left testis tumour.

Lymphoma?

Pathology:
Diffuse large B-cell lymphoma

Testis pathology

- Neoplasm
  - Malignant
  - Benign
- Cyst
- Infection
- Vascular
  - Torsio
  - Infarction
  - Atrophy



DURS
Danish Society of Ultrasonology

Testis ultrasound

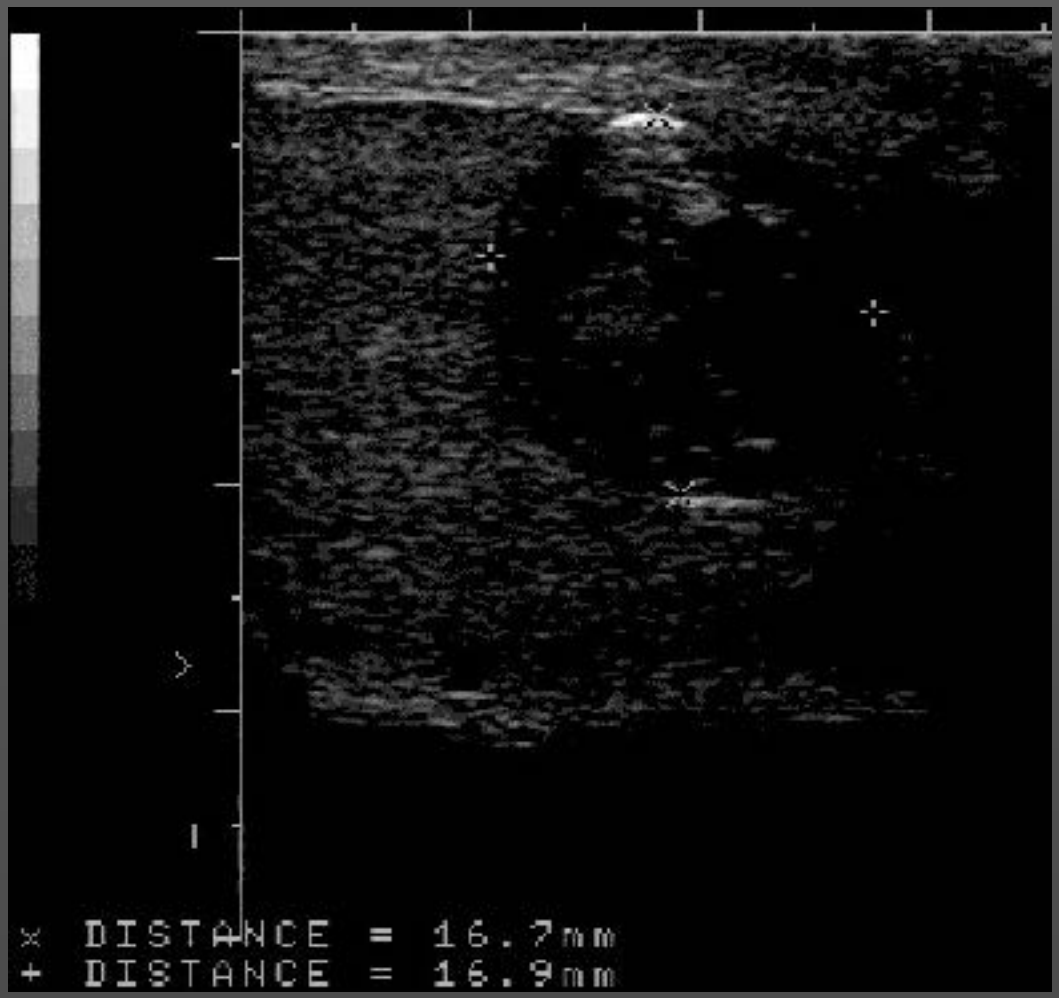

28 year.

Growing left testis.

No other symptoms.

Palpable mass.

Testis ultrasound

28 year.

Growing left testis.

No other symptoms.

Palpable mass.

US: Testis tumour

Pathology: Benign epidermoid cyst

Testis ultrasound

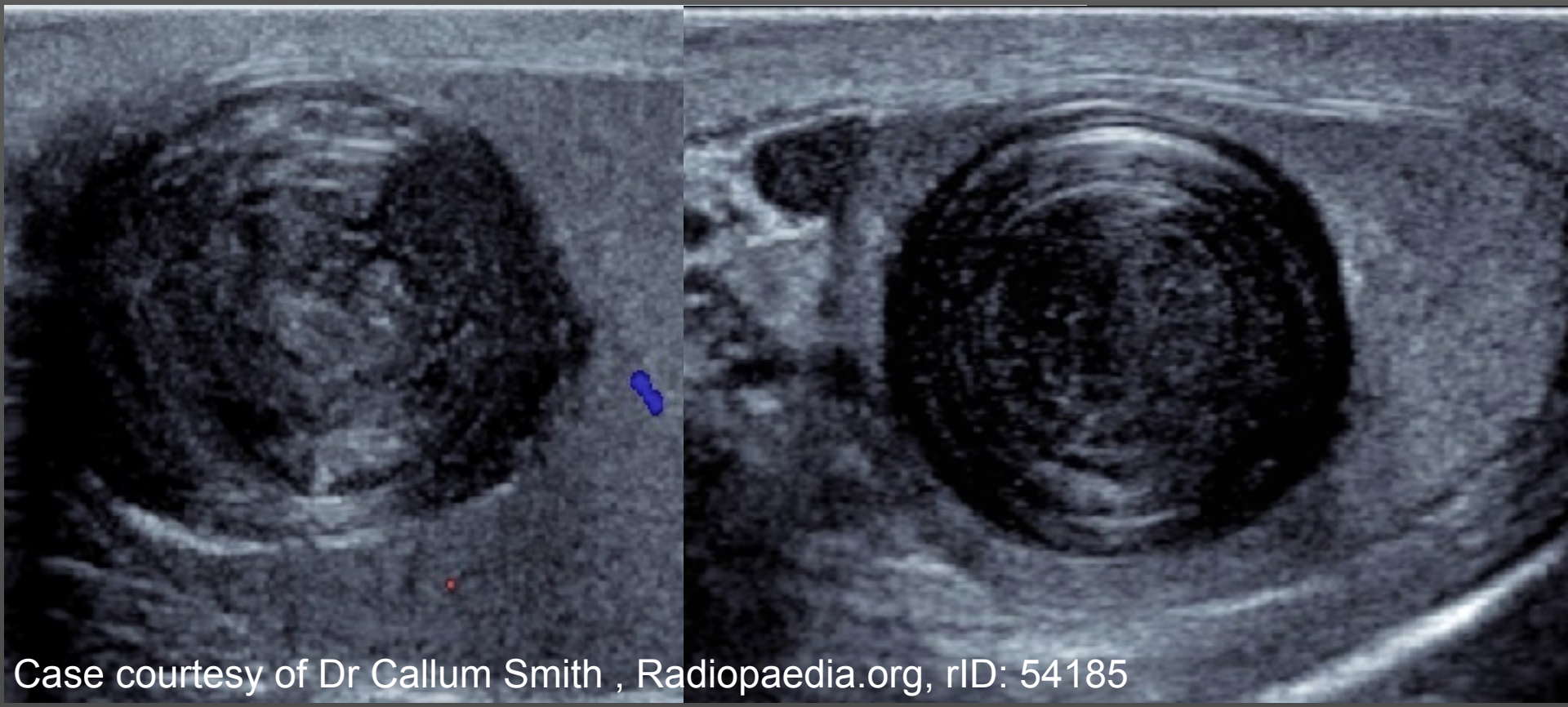

Pathology: Benign epidermoid cyst

Testis ultrasound

5 week old boy.

Swollen right side.

US: Cystic changes in right testis.

Follow-up: Partly regression.



DURS
Danish Society of Ultrasonology

Testis ultrasound

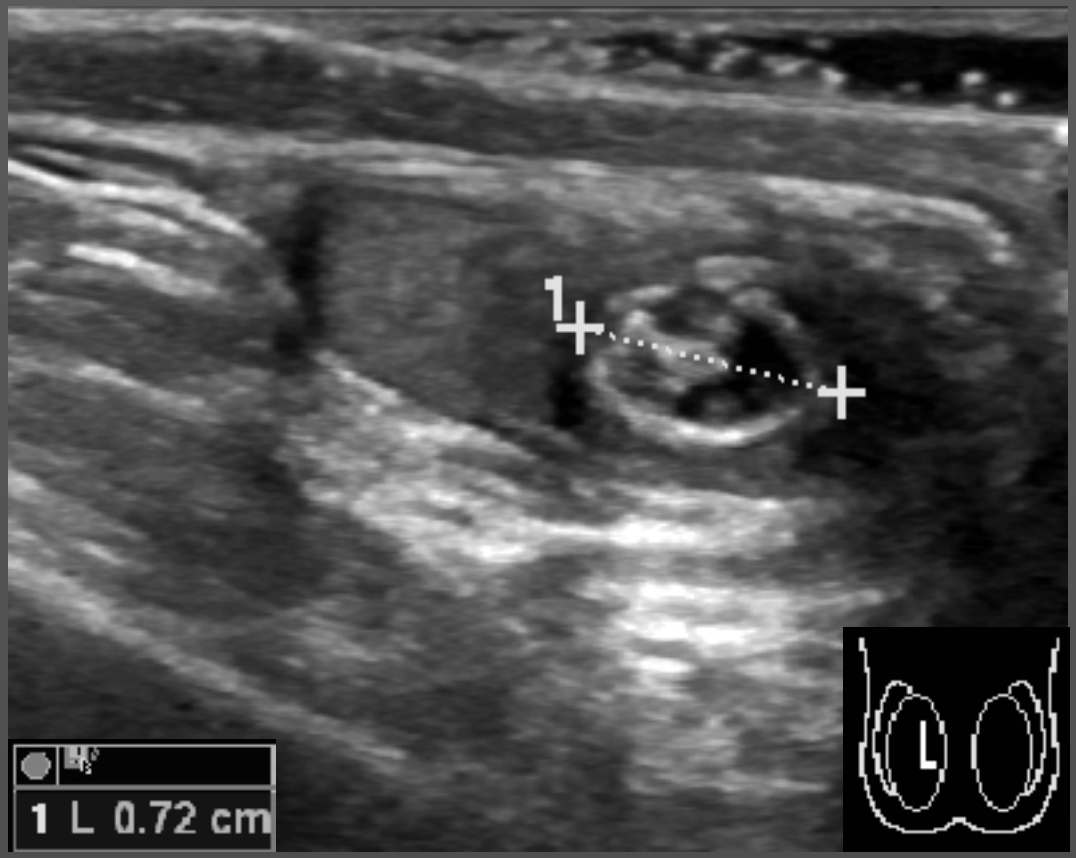

1 year old.

Still cystic-solid lesion in right testis.

Surgery.

Pathology: Benign teratoma

Testis ultrasound

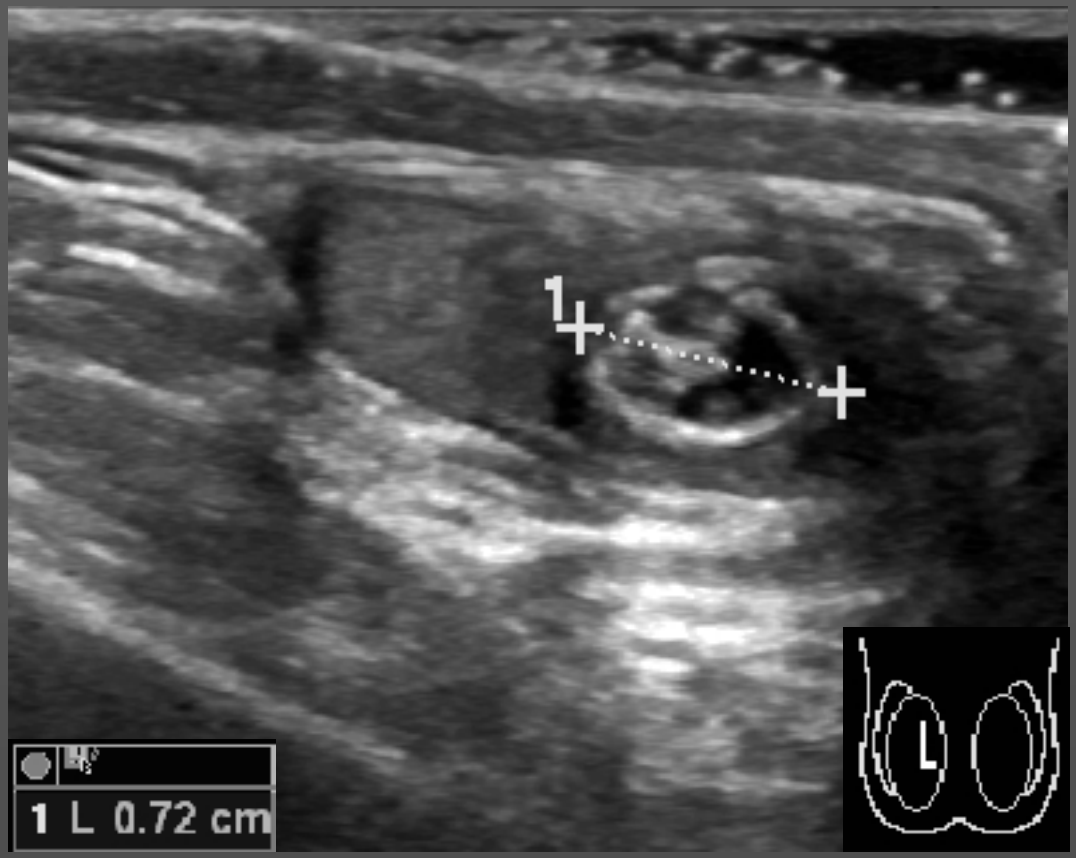

1 year old.

Still cystic-solid lesion in right testis.

Orchiectomy.

Pathology: Benign teratoma

Testis ultrasound

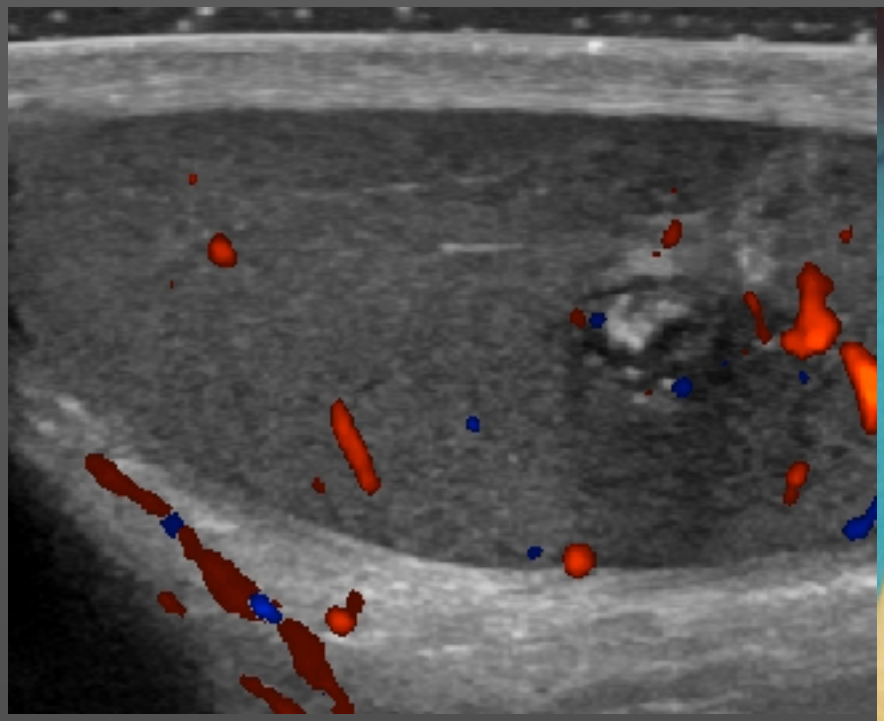

Pathology: Benign teratoma

Testis ultrasound

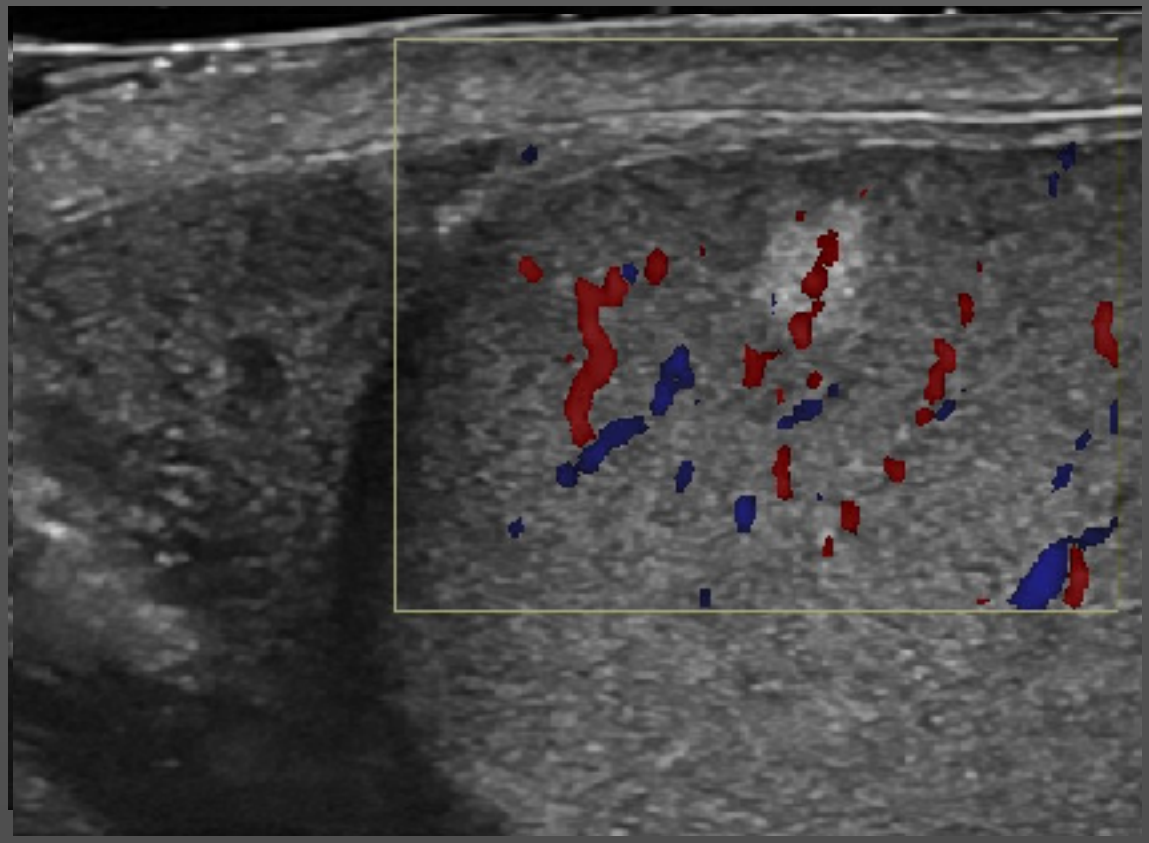

26 year.

Pt. felt little process in left testis. Not really palpable.

US: 3 mm hyperechoic lesion.

Unchanged for 6 months.

Probably benign change.

Neoplastic?

Testis pathology

- Neoplasm
  - Malignant
  - Benign
- Cyst
- Infection
- Vascular
  - Torsio
  - Infarction
  - Atrophy



DUR
Danish Society of Ultrasonology

Testis ultrasound

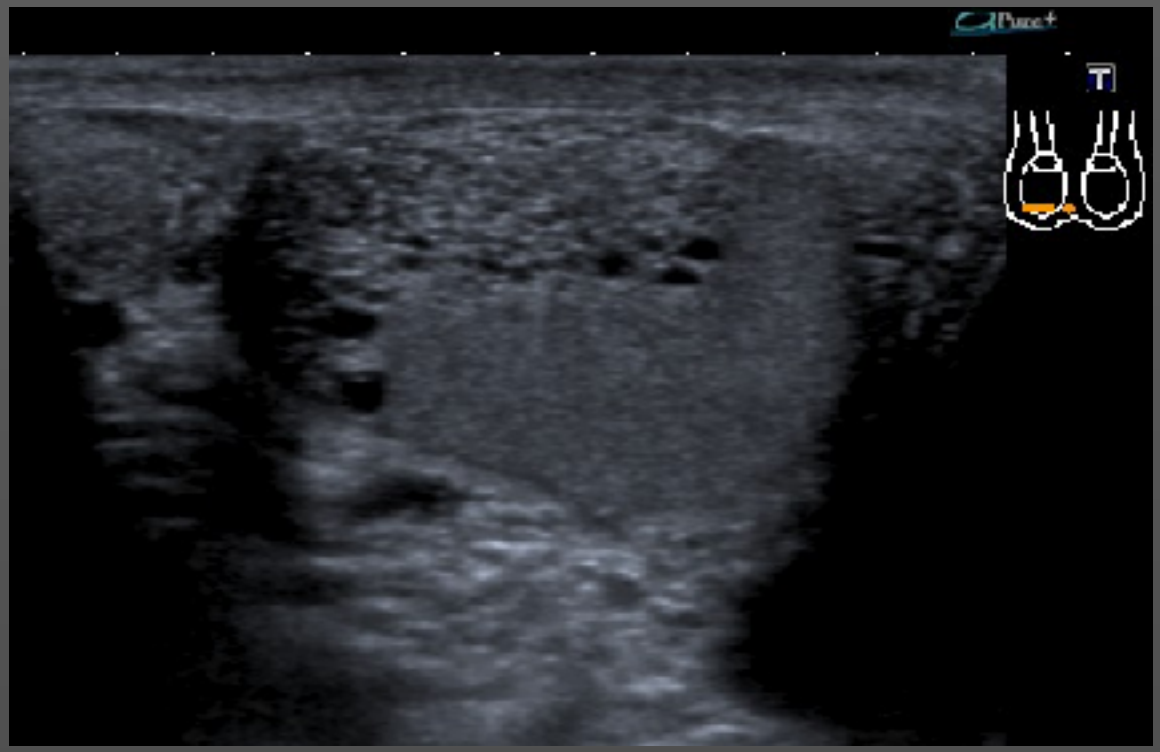

45 year.

Palpable mass in left testis.

Pt. is a doctor!

Dilatation of rete testis

Testis ultrasound

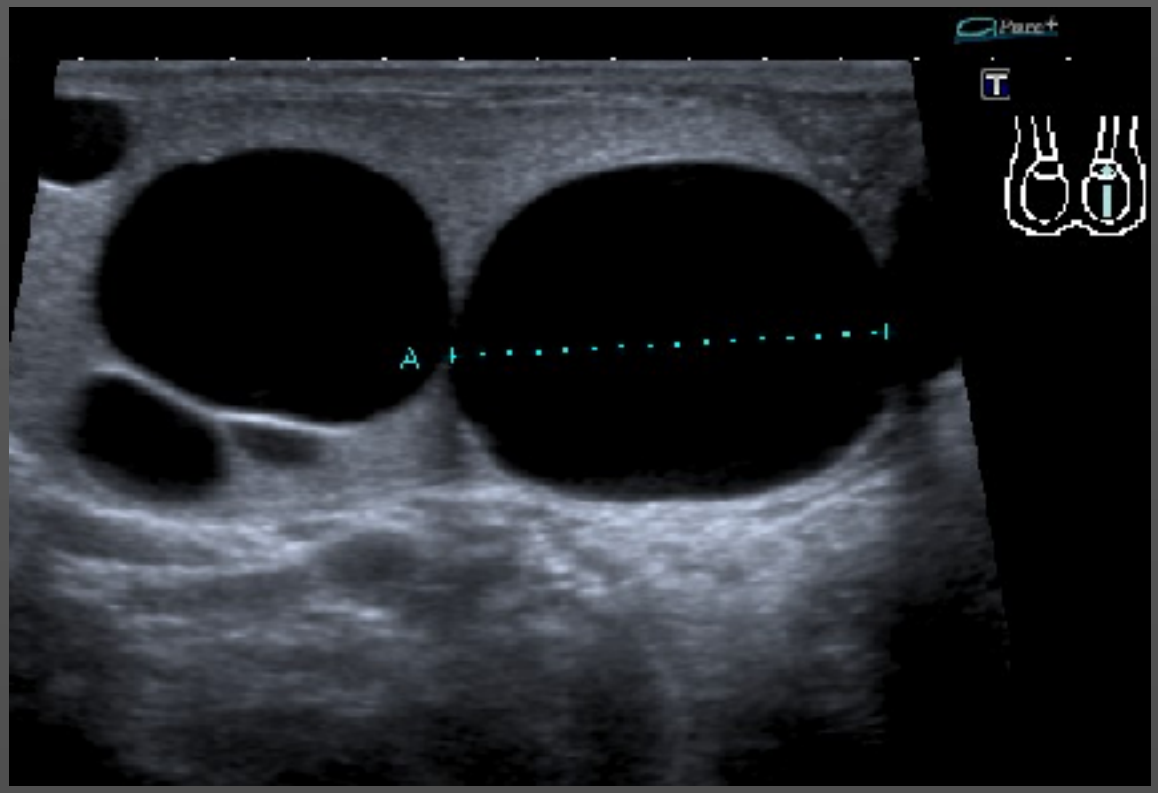

45 year.

Palpable mass in left testis.

Pt. is a doctor!

Cysts – follow-up 1 year, unchanged

DURS
Danish Society of Ultrasonology

Testis pathology

- Neoplasm
  - Malignant
  - Benign
- Cyst
- Infection
- Vascular
  - Torsio
  - Infarction
  - Atrophy



DURS
Danish Society of Ultrasonology

Testis ultrasound

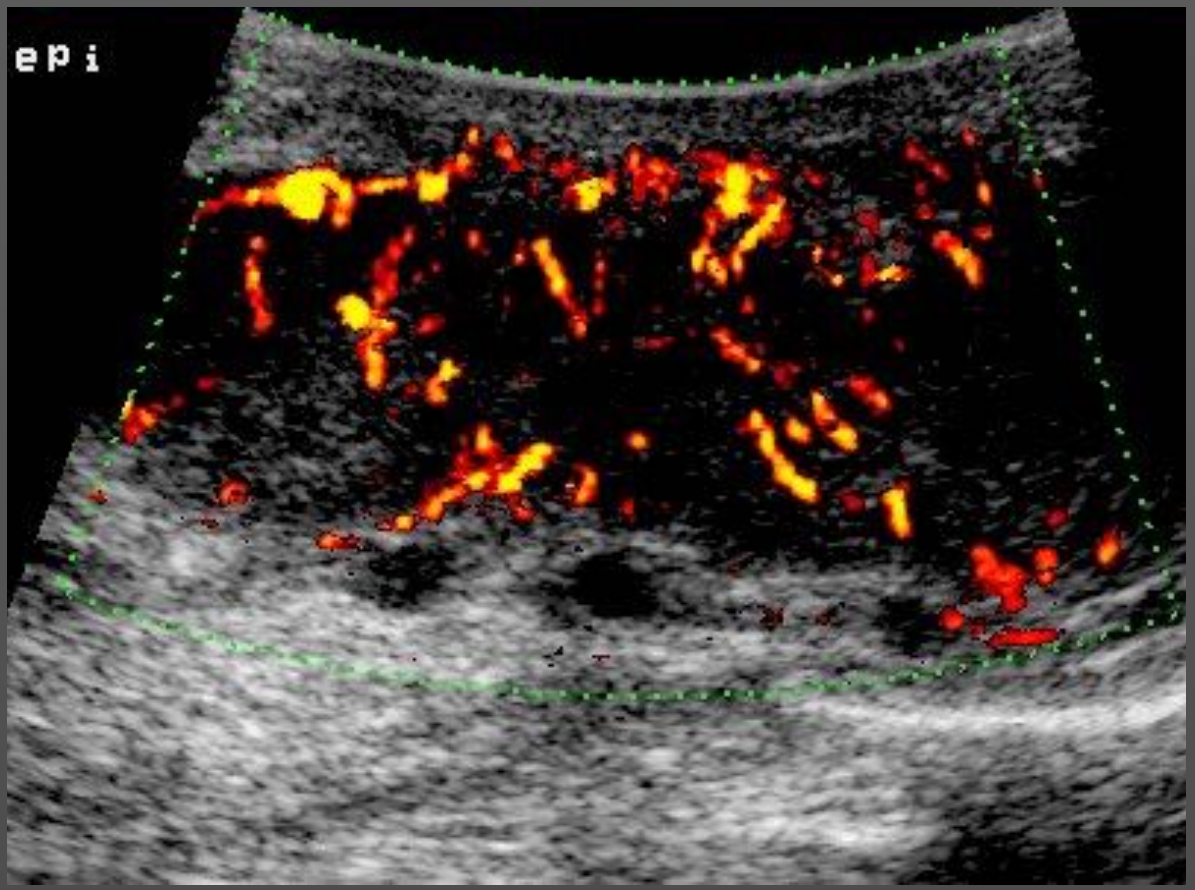

41 year. Clinically epididymitis.



DURS
Danish Society of Ultrasonology

Testis ultrasound

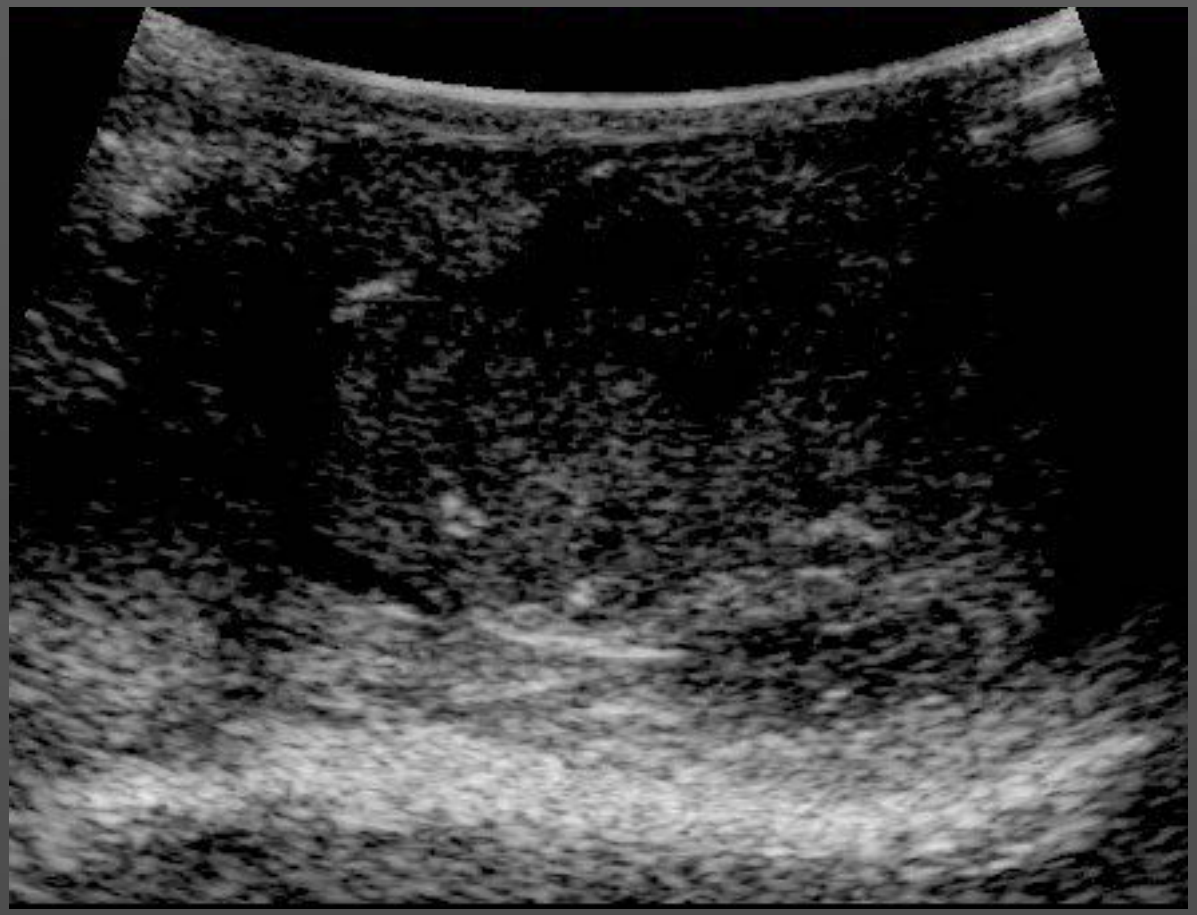

41 year. Clinically epididymitis.



DURS
Danish Society of Ultrasonology

Testis ultrasound

41 year. Clinically epididymitis.

US: Epididymitis and orchitis, small necrosis, recommend follow-up.

Testis ultrasound

41 year.
Epididymitis and orchitis.

7 week follow-up:

Subjectively well.

US: Tumour with extratesticular growth.

Pathology: Seminoma

Testis pathology

- Neoplasm
  - Malignant
  - Benign
- Cyst
- Infection
- Vascular
  - Torsio
  - Infarction
  - Atrophy



DURS
Danish Society of Ultrasonology

Testis ultrasound

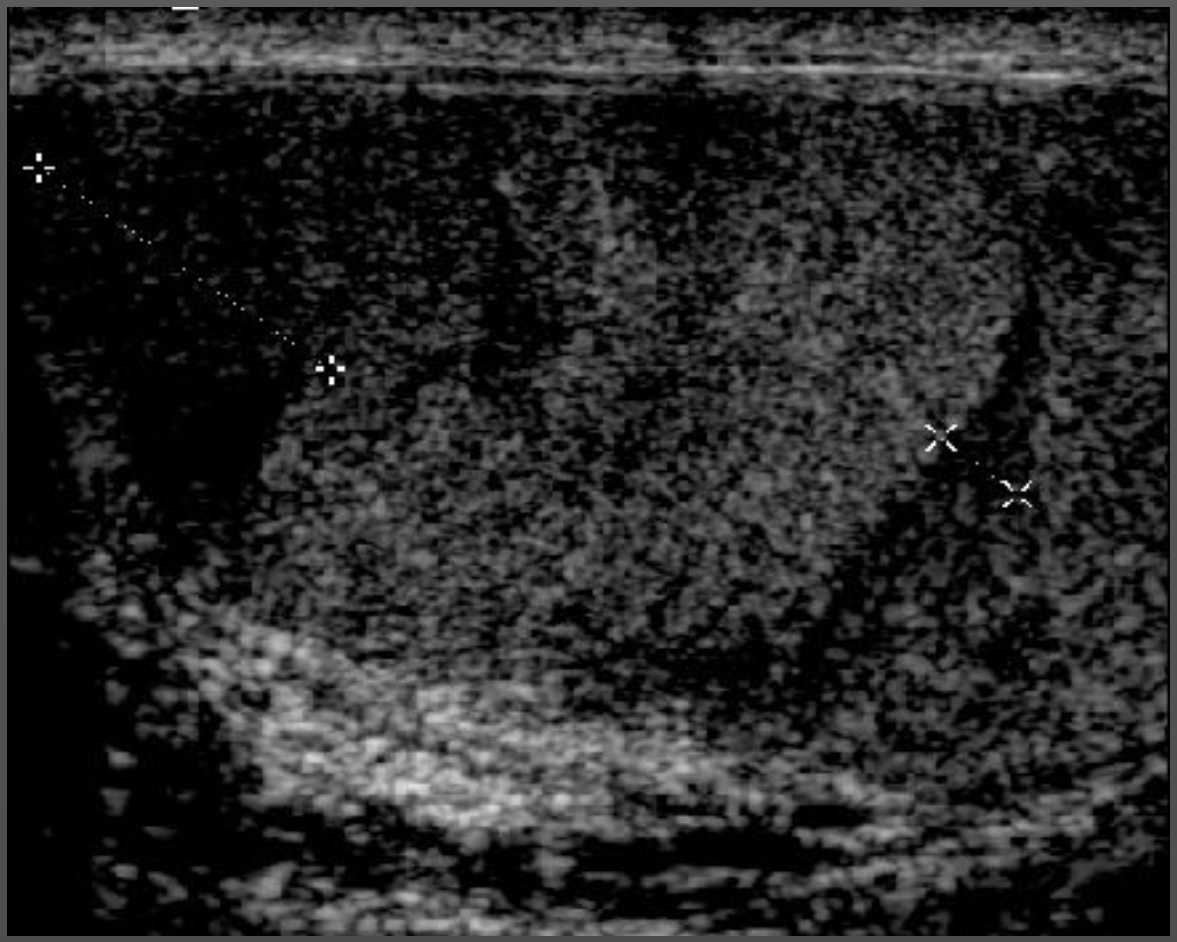

51 year.

Swollen right testis.

Uncertain history.

Testis ultrasound

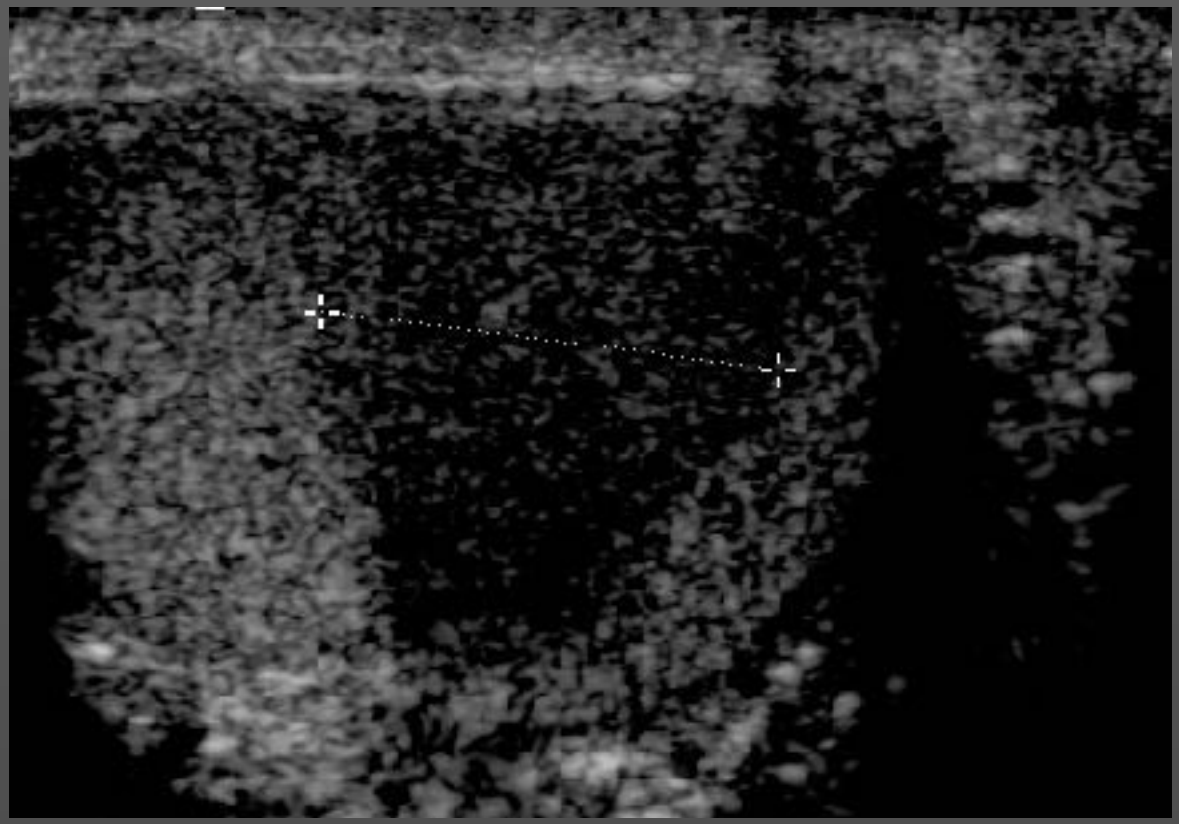

51 year.

Swollen right testis.

Uncertain history.

Testis ultrasound

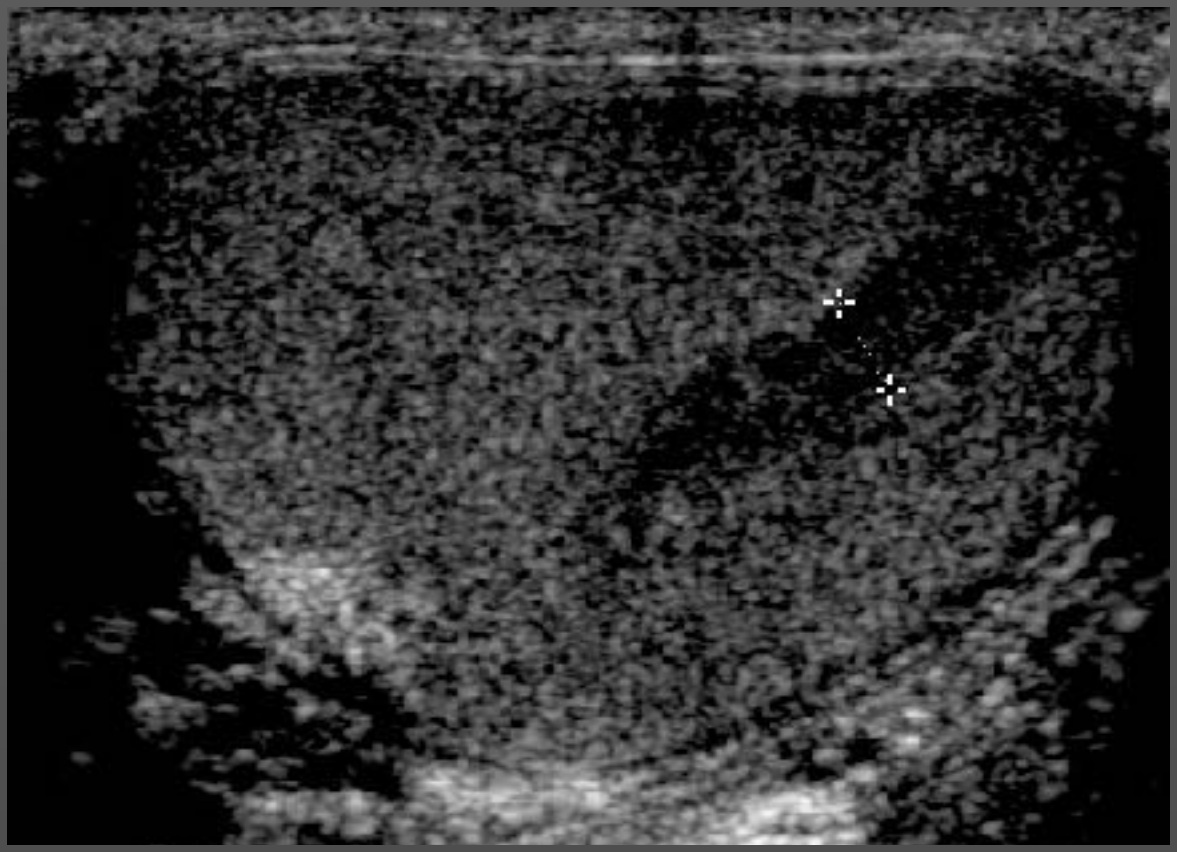

51 year.

Swollen right testis.

Uncertain history.

Testis ultrasound

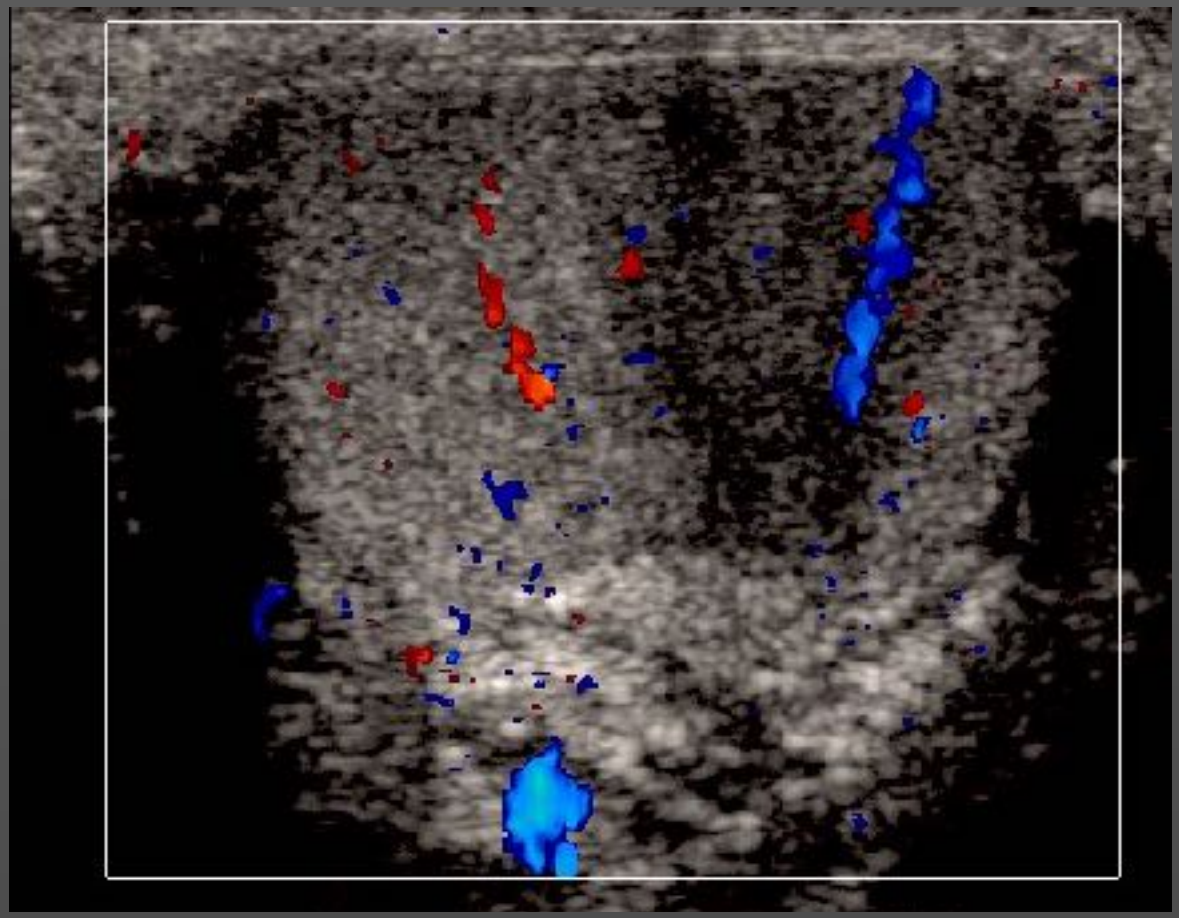

51 year.

Swollen right testis.

Uncertain history.

US: Atrophy/ infarction

probably after orchitis.

Pathology: Fibrosis

Scrotum

Extratesticular mass: Benign

Intratesticular mass: Malignant

- nearly allways



DURS
Danish Society of Ultrasonology

Scrotum

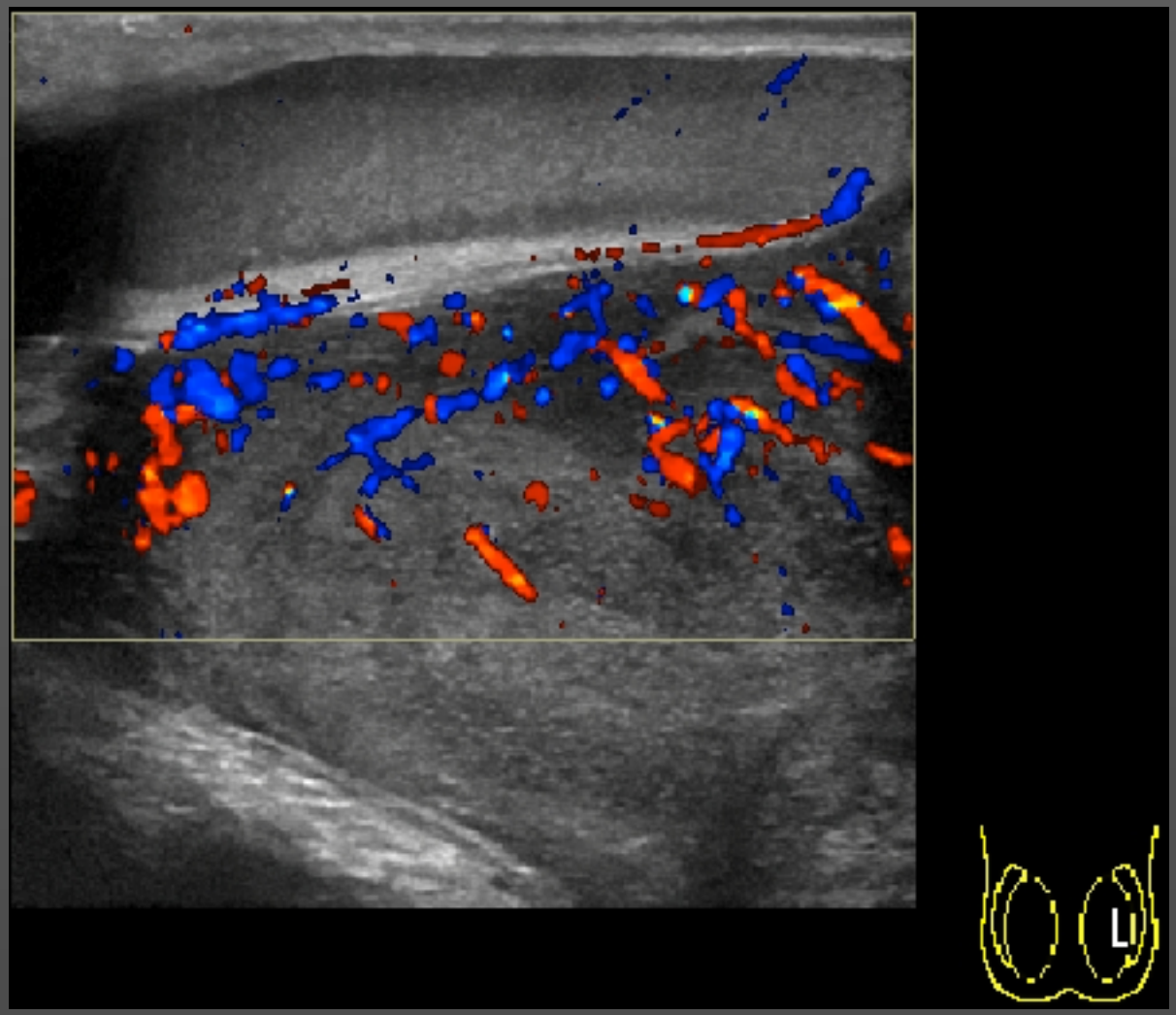

14 year.

Through 1 month mass in scrotum.

Scrotum

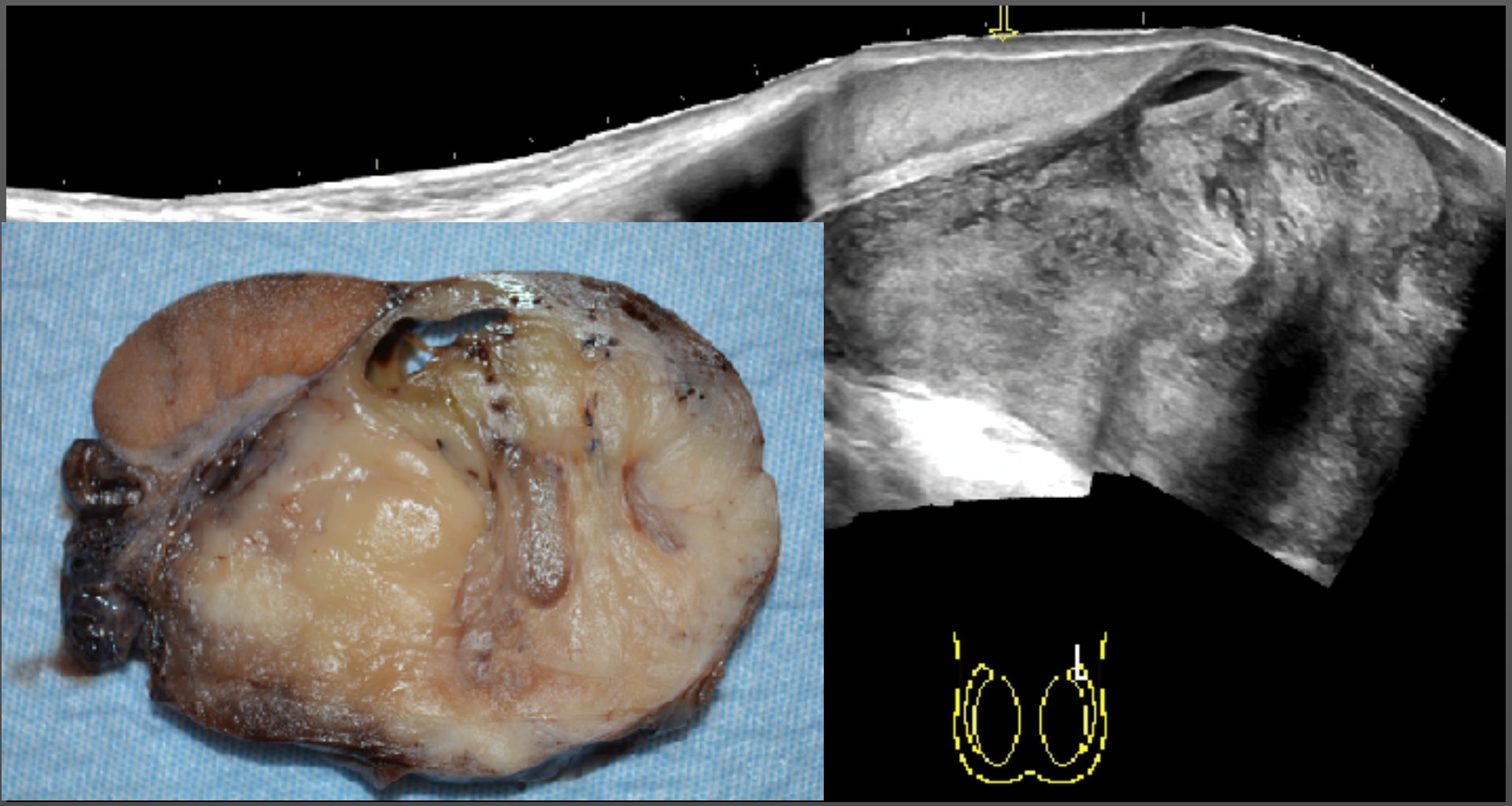

Pathology:
Embryonal rhabdomyosarcoma

Some ultrasound pictures are very old!

Some ultrasound pictures are very old!

Some ultrasound pictures are very old!

Is there really nothing new?

Elastography

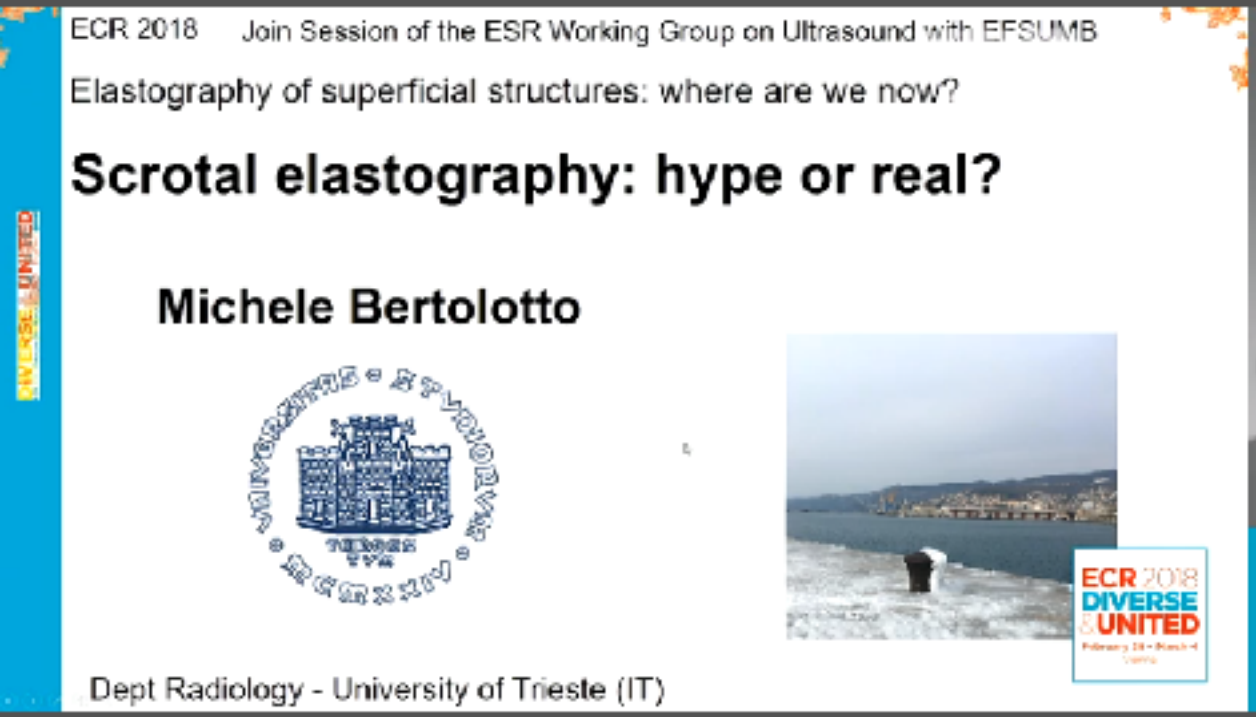

In focal lesions: “Hype”

CEUS

Guidelines & Recommendations

Thieme

The EFSUMB Guidelines and Recommendations for the Clinical Practice of Contrast-Enhanced Ultrasound (CEUS) in Non-Hepatic Applications: Update 2017 (Long Version)

Die EFSUMB-Leitlinien und Empfehlungen für den klinischen Einsatz des kontrastverstärkten Ultraschalls (CEUS) bei nicht-hepatischen Anwendungen: Update 2017 (Langversion)

Authors

Paul S. Sidhu[1], Vito Cantisani[2], Christoph F. Dietrich[3], Odd Helge Gilja[4], Adrian Saftoiu[5], Eva Bartels[6], Michele Bertolotto[7], Fabrizio Calliada[8], Dirk-André Clevert[9], David Cosgrove[10], Annamaria Deganello[1], Mirko D'Onofrio[11], Francesco Maria Drudi[12], Simon Freeman[13], Christopher Harvey[14], Christian Jenssen[15], Ernst-Michael Jung[16], Andrea Sabine Klauser[17], Nathalie Lassau[18], Maria Franca Meloni[19], Edward Leen[20], Carlos Nicolau[21], Christian Nolsoe[22], Fabio Piscaglia[23], Francesco Prada[24], Helmut Prosch[25], Maija Radzina[26], Luca Savelli[27], Hans-Peter Weskott[28], Hessel Wijkstra[29]

DURS
Danish Society of Ultrasonology

CEUS

Tumors and complex cysts

The current understanding is that testicular tumors with a diameter of less than 1.5 cm may not show flow on color Doppler US and thus may be misinterpreted as a benign lesion, the purported hallmark of malignancy being an increase in vascularity [84]. Simple testicular cysts are usually benign, but any wall irregularity or echogenic debris may be suggestive of a (rare) cystic testicular tumor [85, 86]. CEUS is able to confirm the absence of vascularity in benign complex cysts and epidermoid cysts [87, 88]. It is thought that virtually all testicular tumors display vascularization on CEUS, with the exception of any cystic component and regions of necrosis. Very rare exceptions may be represented by extensively necrotic lesions, and by the so-called "burned out" testicular tumor [89 – 91].



CEUS

RECOMMENDATION 14

CEUS can distinguish vascularized from non-vascularized focal testicular lesions, helping to exclude malignancy (LoE 1a, GoR A). Strong consensus (20/0/0, 100 %)

RECOMMENDATION 16

CEUS can identify segmental infarction (LoE 2b, GoR B). Strong consensus (20/0/0, 100 %)



DURS
Danish Society of Urroradiology

Take home messages

- US discriminates between intra- and extratesticular masses (“surgery or not!”)
- US can characterize most intratesticular benign changes
- CEUS can in selected cases help to characterize intratesticular changes



DURS
Danish Society of Ultrasonology

Thank you for your attention